

Evaluation of the gonad volume throughout Magnetic Resonance Imaging in *Crassostrea gigas* and comparison with histological method

Emilie FLAHAUW¹, Armel DAVENEL², Stéphane QUELLEC², Virgile QUILLIEN³, Lionel DEGREMONT¹, Sylvie LAPEGUE¹, Philippe-Jacques HATT¹

1. Ifremer, LGP, Avenue de Mus de Loup, 17390 La Tremblade, France
2. Irstea, IRMFood, 17, avenue de Cucillé, 35044 Rennes Cedex
3. Ifremer, UMR LEMAR, 29280 Plouzané, France

Email: emilie.flahauw@ifremer.fr



Introduction

Biological parameters of the cupped oyster *Crassostrea gigas* such as growth, reproductive effort (duration of the gametogenesis, date of spawning, and fecundity) differ widely among oysters in the same location. Furthermore, most of the traditional methods, like histological observations, could lead to large variability on the observations and the measurements of these traits, and large uncertainties on their changes over time. These can be drastically reduced by using Magnetic Resonance Imaging (MRI) which is a non invasive method allowing to measure the same individual during its development.

Materials & Methods

- 300 oysters observed for 6 MRI sessions (fig. 1A):
 - 5 during gametogenesis (April, May, June, July, August)
 - 1 session after gametogenesis
 - Gonad area and volume estimated by number of voxels in grey levels higher than 166
- 40 oysters sacrificed for histology after 3 MRI sessions (fig. 1B):
 - 10 in April,
 - 10 in May,
 - 20 in June.
 - Gonad area measured on histological slides by number of pixels composing gonadic cells




Figure 1: Sections of one oyster by MRI (A) and by histology (B). Gonad (a) appears in higher greyscale on MRI slice and in dark purple on histological slide. On both pictures, visceral mass (b) and gills (c) can also be observed.

Results

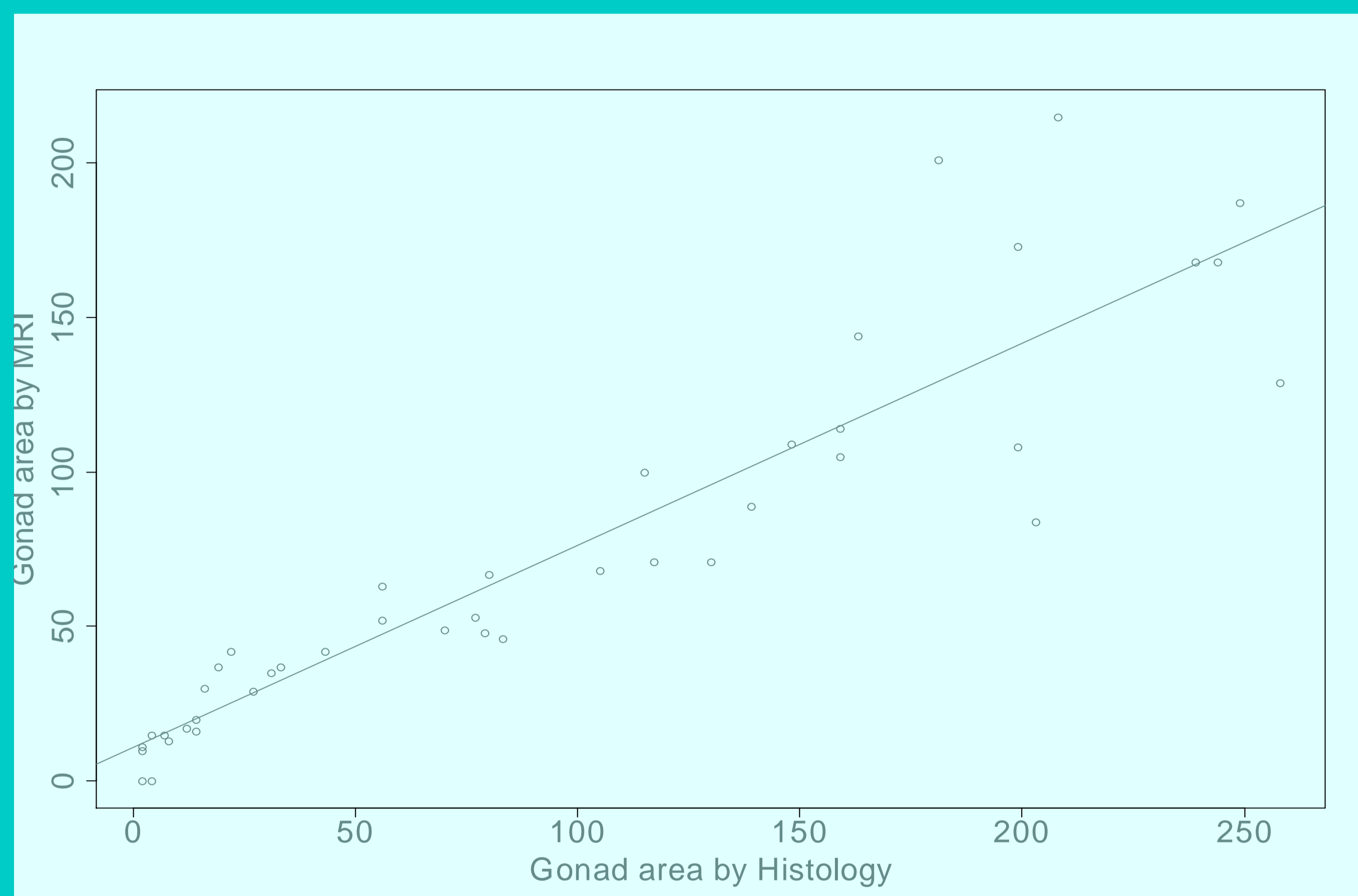


Figure 2: Gonad surface on histological slide and gonad surface by use of MRI.

This highly significant linear relationship between the two methods ($R^2=0.84$) allows us to use MRI instead of histology to monitor reproductive effort of oysters.

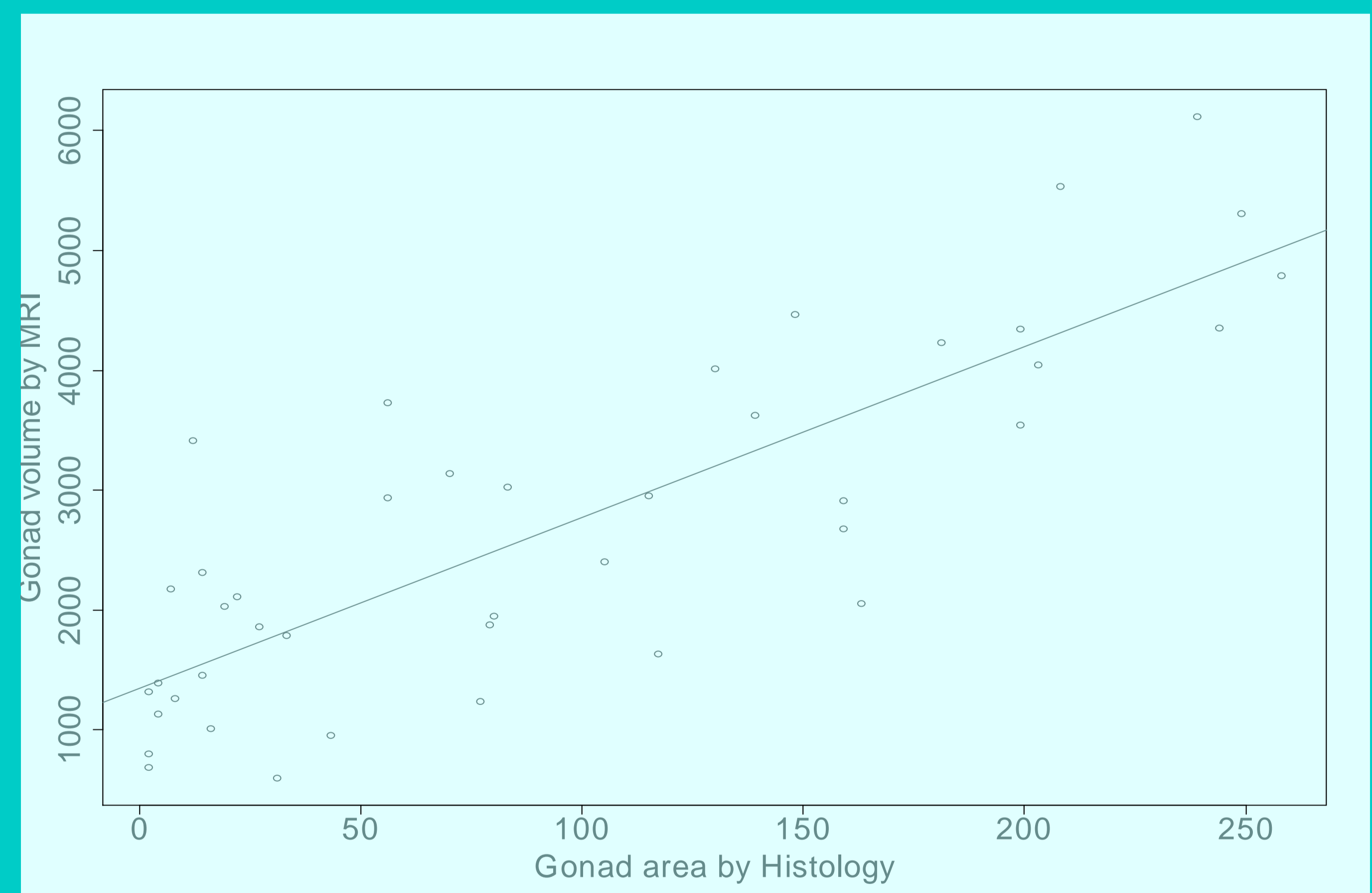


Figure 3: Gonad surface on histological slide and gonad volume by use of MRI.

This highly significant linear relationship between the two methods ($R^2=0.68$) demonstrate that MRI is appropriate to assess the reproductive effort of Pacific oysters.

Conclusion & Perspectives

MRI is a non-destructive method which makes it possible to assess individual evolution of reproductive effort and to compare individuals with a precision level as good as with traditional and destructive method of histology.

However, it remains to reduce measurement uncertainties due mainly to the voxel size: a voxel might contain gonadic and somatic cells (eg vesicular cells). This can therefore lead to an overestimation of gonad volume.

Results from this study will allow us to try to detect parts of the genome (QTLs) correlated to reproductive effort of *Crassostrea gigas*.