

# Can *Bonamia ostreae* infect larvae of flat oysters *Ostrea edulis* ?

Isabelle Arzul<sup>1</sup>, Bruno Chollet<sup>1</sup>, Maeva Robert<sup>1</sup>, Emmanuelle Omnes<sup>1</sup>, Céline Garcia<sup>1</sup> and Aimé Langlade<sup>2</sup>.

1. IFREMER, LGP, av de Mus de Loup, 17390 La Tremblade, France –

2. IFREMER, LER/MPL La Trinité, 12 rue des Résistants, BP 26, 56470 La Trinité-sur-Mer, France

## Introduction

*Bonamia ostreae* is an intracellular protistan parasite affecting flat oysters *Ostrea edulis*. It can be detected in juveniles but mortalities mainly affect oysters which are more than 2 years old. The parasite is usually observed inside haemocytes and sometimes free in gill and digestive epithelia suggesting a parasite release through these organs. However, the infective form and ways of entry and release remain undetermined. A controversial description proposed that *B. ostreae* was an ovarian tissue parasite for part of its life cycle but this hypothesis could never be later confirmed.

Flat oysters keep larvae in the mantle cavity for 10 to 12 days after fecundation and before releasing them in the water column. This period could favor transmission of pathogens like *Bonamia ostreae* between adults and larvae.

In the context of a survey carried out in Quiberon bay (France) to control the presence of larvae within flat oysters, histology, *in situ* hybridization and PCR were used in order to test the presence of *Bonamia ostreae* within adults and their larvae.

The detection of the parasite in adults and also their offspring raises some questions about the transmission of the parasite from spawners to larvae as well as the role played by larvae in the disease spread.

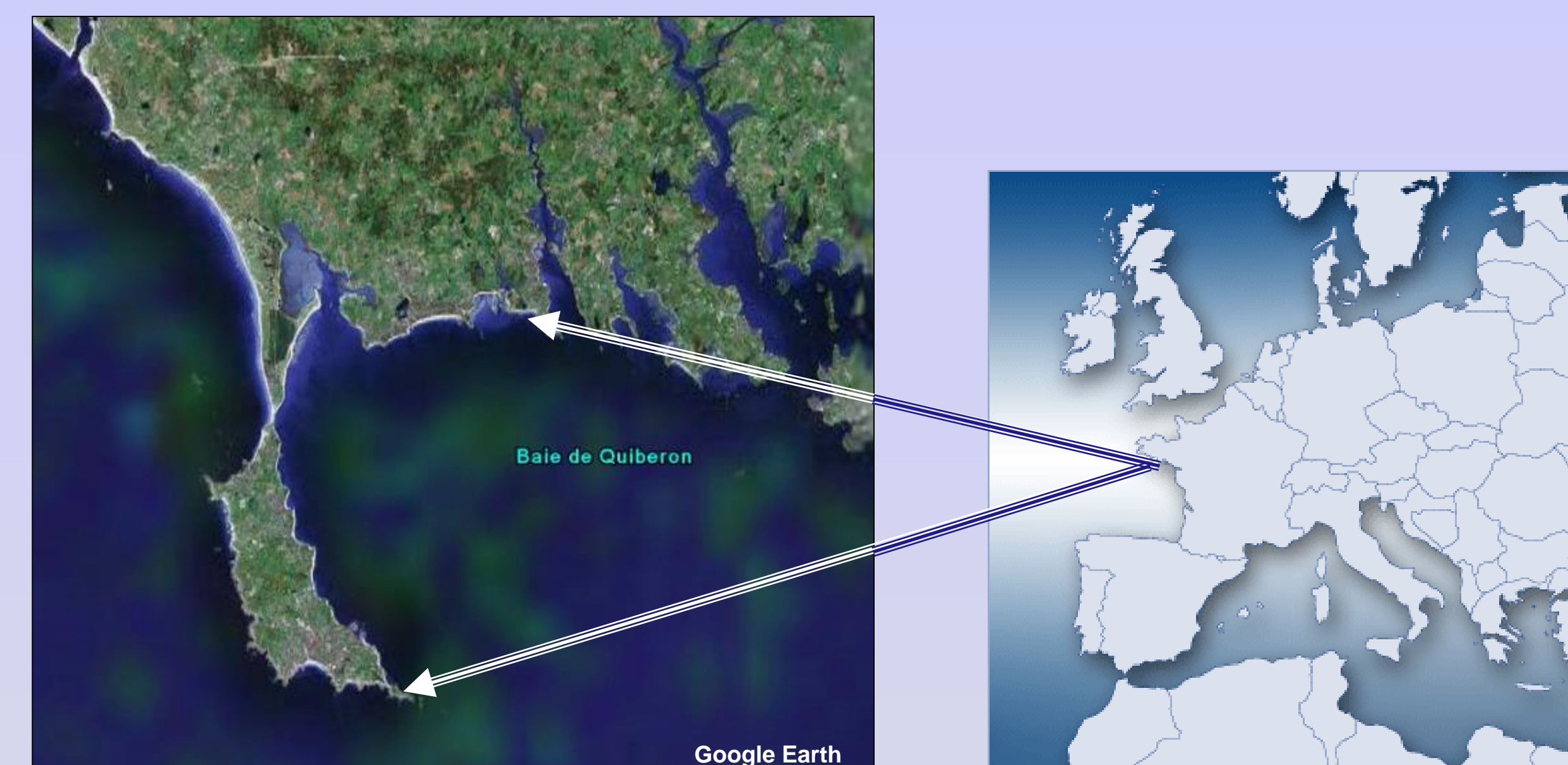


Figure 1 - Quiberon Bay, Southern Brittany, France

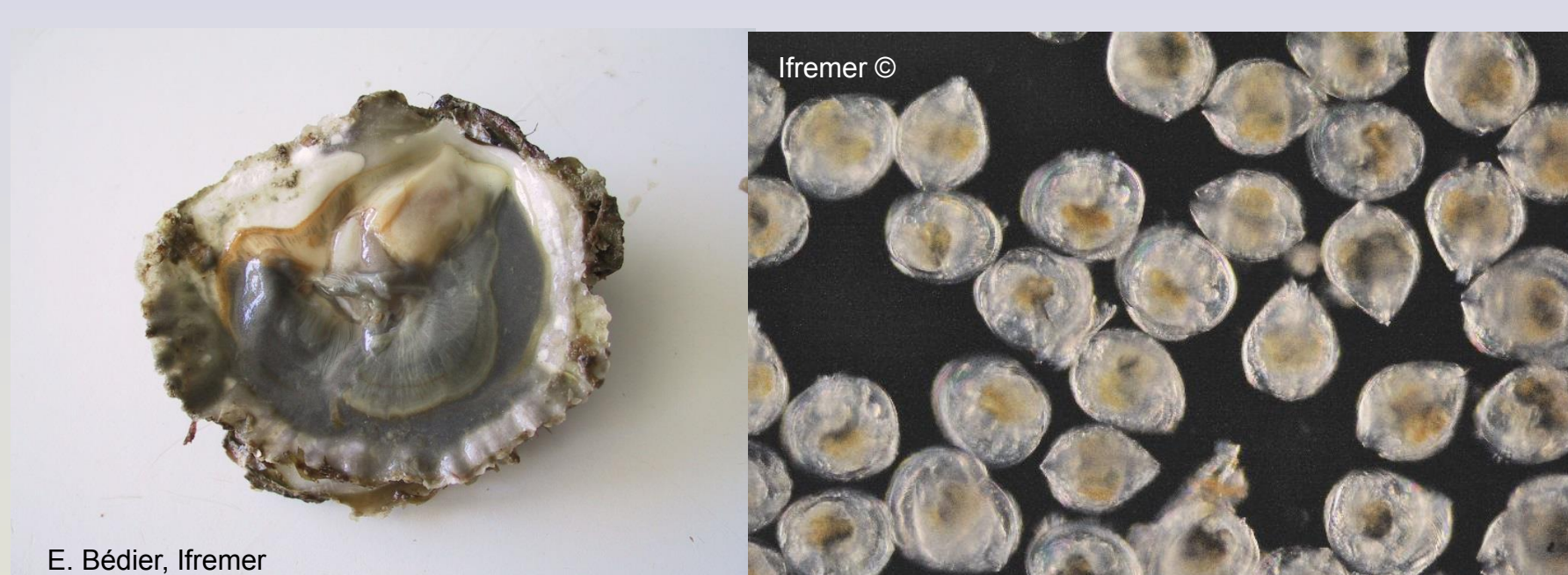


Figure 2 - Flat oyster incubating larvae- Larvae of flat oysters

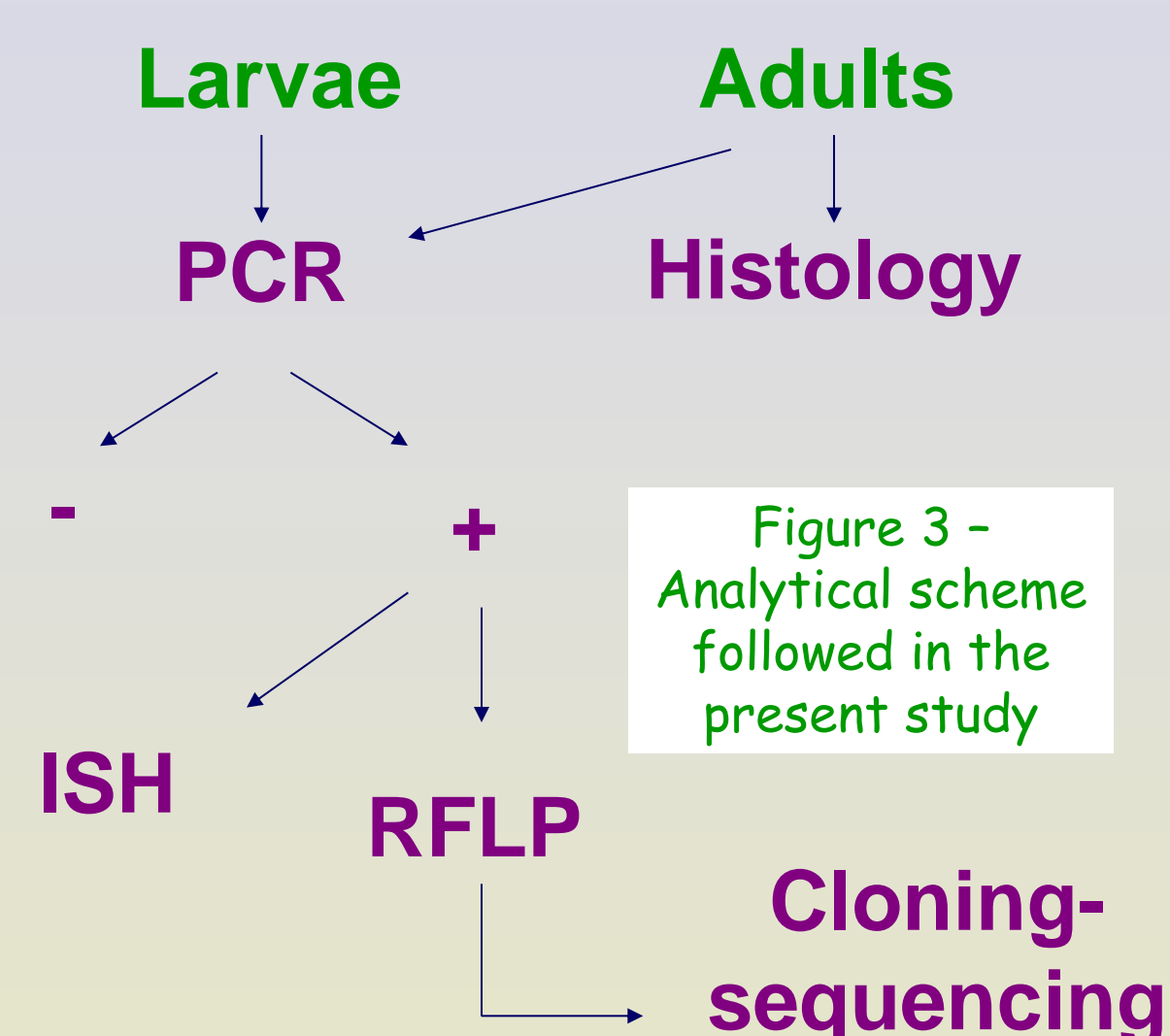


Figure 3 - Analytical scheme followed in the present study

## Results (See Table I)

- 31 and 53 oysters incubating larvae could be obtained in 2007 and 2008 respectively.
- Histological examination revealed the presence of parasites similar to *Bonamia ostreae* in 11 out of the 84 tested oysters.
- In 2007, 5 out of the 31 tested spawners and 1/31 of the larvae samples yielded positive signal by PCR. The adult corresponding to this positive larvae sample was found infected by PCR as well.
- In 2008, 10 and 9 of the 53 tested samples were found positive by PCR for the adults and larvae respectively. Three of the adults had positive signal in corresponding larvae samples.
- PCR products were tested by RFLP and all the restriction profiles were similar to *B. ostreae* ones except for one sample of larvae which exhibited *B. exitiosa* like profiles (Figure 4f).
- Two PCR products showing *B. ostreae* and *B. exitiosa* profiles were cloned and 2 -3 clones were sequenced. Sequences confirmed RFLP results.
- ISH tests performed on samples found positive by PCR allowed observing positive signal in 15 and 6 of the adults and larvae samples respectively (Figures 4a-e).

		Adults	Larvae samples	Adult-Larvae
2007	PCR	5/31	1/31	1/31
	ISH	2/5		
	histology	2/31		
31 incubating oysters	Total positive	5/31	1/31	1/31
2008	PCR	10/53	9/53	3/53
	ISH	13/16	6/9	4/53
	histology	9/53		
53 incubating oysters	Total positive	17/53	9/53	6/53

Table I - Synthesis of positive results obtained by PCR, ISH, histology or all techniques combined for adults and larvae samples. The column "Adult-Larvae" indicates the number of cases for which adults and their offspring were found positive.

## Conclusion

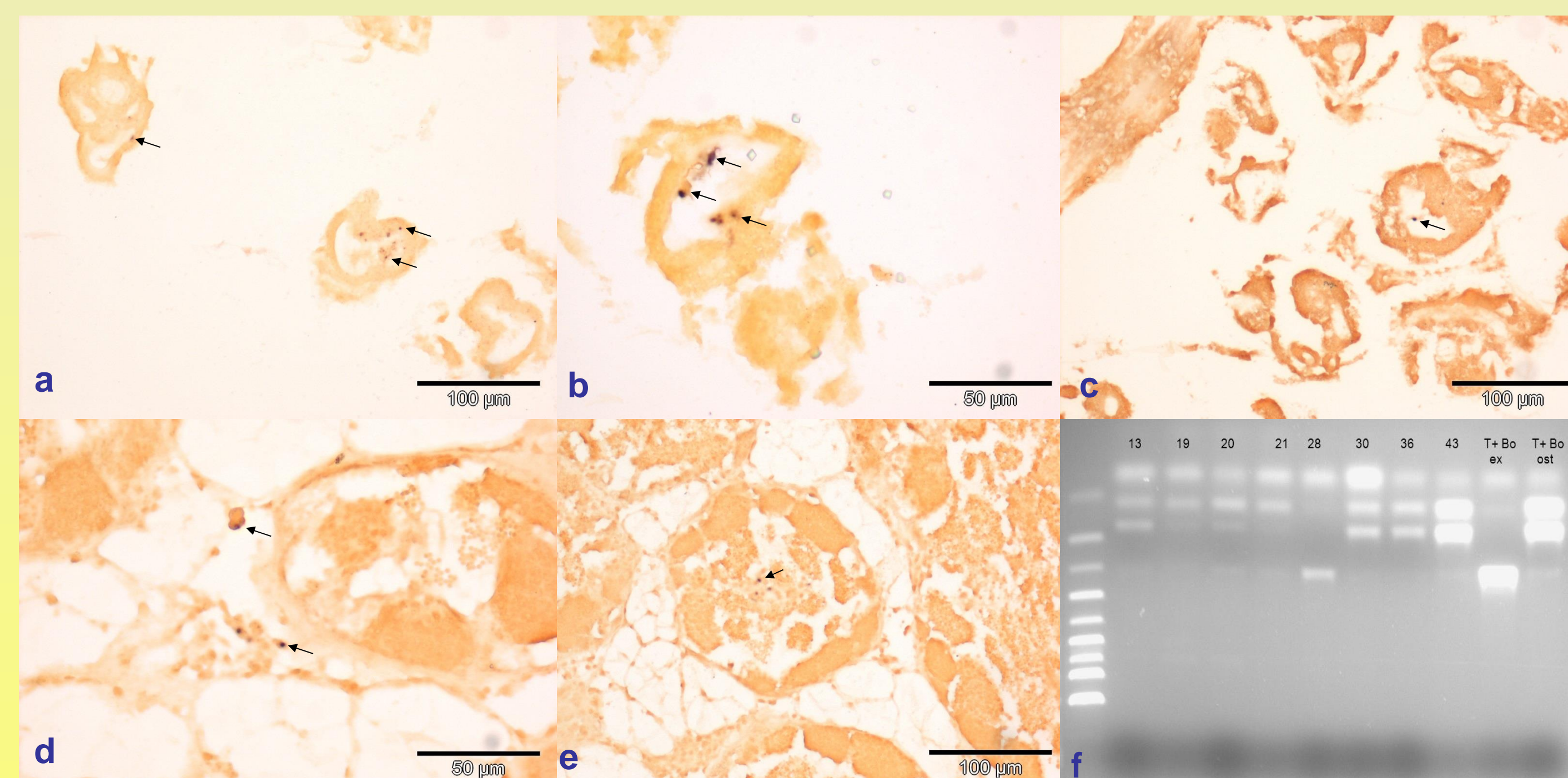
Positive results obtained by PCR and confirmed by *in situ* hybridization are indicative of an infection of adults but also of larvae by the parasite *Bonamia ostreae*. DNA from *B. exitiosa* like parasite was also detected in one sample of larvae. For the first time it is shown that the parasite *B. ostreae* is able to infect young stages such as larvae. These results suggest that the parasite could be transmitted from adults to larvae during the period of incubation of larvae. Larvae might thus present some risks of *B. ostreae* spread and their transfers should consequently be controlled.

## References

- Cochennec N., Le Roux F., Berthe F. And A. Gérard. 2000. Detection of *Bonamia ostreae* based on small subunit ribosomal probe. Journal of invertebrate pathology 76(1): 26-32.  
 Cochennec N., Reece KS, Berthe FCJ, Hine PM. Revisiting *Mikrocytos roughleyi* taxonomic affiliation points to the genus *Bonamia* (Haplosporidia). Dis Aquat Organ 2003;54:209-217.  
 Hine PM, Cochennec-Laureau N, Berthe FCJ. *Bonamia exitiosus* n. sp. (Haplosporidia) infecting flat oysters *Ostrea chilensis* (Philippi) in New Zealand. Dis Aquat Organ 2001;47:63-72.

## Material and Methods

- Spawners were collected weekly by diving in Quiberon Bay (Figure 1) between May and August of 2007 and 2008. Spawners were then opened and oysters incubating larvae (Figure 2) were selected for subsequent analyses to test the presence of the parasite *Bonamia ostreae*.
- Larvae collected in 2008 and tissue sections from oysters collected in 2007 and 2008 were fixed in Davidson's fixative for histology and *in situ* hybridization (ISH) analyses. Larvae and gills from adults were fixed in ethanol for molecular analyses.
- DNA extraction was performed using the QIAamp DNA minikit (Qiagen) according to the manufacturer's instructions.
- PCR and ISH were realised according to Cochennec et al. (2000) using Bo Boas primers and probe respectively.
- PCR products were tested by RFLP using *Bgl*I and *Hae*III (Hine et al. 2001; Cochennec et al. 2003).
- Some PCR products were cloned using the TOPO TA cloning kit (Invitrogen) and 2-3 clones per PCR product were bidirectionally sequenced using the Big Dye V3 sequencing kit (Applied Biosystem, U.S.A.).
- The analytical scheme followed during this study is summarised in Figure 3.



Figures 4 - Positive signal observed in some larvae samples (a and b), in larvae on adult section (c) and in some adults (d and e) by *in situ* hybridization. Note the dark labelling in cells around the visceral cavity in larvae and in the connective tissue around the gonad in some adults. PCR-RFLP (*Bgl*I) test of larvae samples collected in 2008 (f): sample 28 shows *B. exitiosa* restriction profile while other tested samples exhibit *B. ostreae* restriction profiles.

Pictures a-e are from B. Chollet and picture f is from M. Robert