

12

Recent advances in Australian prawns diseases and pathology

L. OWENS and S. HALL-MENDELIN

Graduate School of Tropical Veterinary Science, James Cook University of North Queensland, TOWNSVILLE, Australia, 4811.

Abstract — Australian penaeid mariculture is undergoing a rapid expansion. Disease is always limiting in animal production and new syndromes occur in fledgling industries. This paper describes the latest findings in this area. RNA proliferation was seen in the ovaries of *Metapenaeus ensis* from the Torres Strait and was believed to have a viral aetiology. Idiopathic hypodermal, haematopoietic and myocardial necrosis has been associated with a number of conditions. Haematopoietic changes include vacuolative necrosis, reactive hyperplasia with nuclear transformation tending towards anaplasia and rarely, small eosinophilic inclusion bodies. A coccidian was found in the hepatopancreatic cells of *Penaeus merguensis* and elicited a marked cellular response with hyperplasia and nuclear transformation. Dinoflagellates have also been found attached to nauplii. Bungoo or rhinoceros disease has also been seen in northern hatcheries. *Vibrio damsela* was shown to be a primary pathogen of nauplii and caused a septicaemia. Vacuolation and shrinkage of the ganglionic neuropiles as well as muscular fragmentation and coagulative necrosis were common. Other bacteria caused similar changes but were unable to produce a septicaemia.

Problems with *Macrobrachium rosenbergii* in northern Australia include mid-cycle disease, microsporidiosis and bopyridiasis. *M. rosenbergii* from Malaysia have been infected with Hepatopancreatic Parvo virus.

INTRODUCTION

Australian penaeid mariculture is undergoing a rapid expansion. Disease is always limiting in animal production and new syndromes occur in fledgling industries. Such has been the case in Australia. A recent review describes some of the diseases of penaeid prawns seen in north Queensland (Owens and Hall-Mendelin, 1989). This review updates that previous report and complements the material on other Australian penaeid diseases by R.G.J. Lester in this book. Only new or unreported entities will be included herein. Diseases reported in the previous review include Plebejus baculovirus, Hepatopancreatic Parvovirus, Chlamydia, Microsporidia, bacteria, Lagenidium, hypodermal necrosis, cramp tail and vitamin E deficiency.

MATERIALS AND METHODS

The greatest majority of prawns were submitted from aquaculture farms. Live prawns were slowed by cooling and then fixed in Davidson's fixative after the cephalothorax had been split longitudinally. Normal histology and staining was performed as in Culling *et al.* (1985).

A carton of commercially caught *Metapenaeus ensis* from Torres Strait were purchased from a trawler operator at Weipa in June 1982. The samples were already frozen and later fixed in 10 % buffered normal formalin. The first abdominal segment was cut transversely and prepared using standard histological techniques. Material for electronmicroscopy was deparaffinized, postfixed in osmium tetroxide and embedded in Spurr's resin (Culling *et al.*, 1985). Sections of approximately 70-90 nm were cut with the ultramicrotome and stained with uranyl acetate and lead citrate before viewing under the transmission electronmicroscope. Semi-thin epoxy resin sections (1-2 μm) were stained with Toluidine blue and Fuchsin following the method of Burns and Bretschneider (1981).

For histopathology, protozoa were fixed in 10 % seawater formalin and postfixed in Davidson's fixative with eosin added. The larvae were then washed in tap water and 10 % agar was poured on top. After the agar cooled, it was fixed in formalin and processed using standard histological techniques. Three μm sections were cut and stained with either haematoxylin and eosin or gram Twort.

RESULTS

I Adults prawns

Wild caught female spawners of *P. merguensis* were showing low tolerance to transportation. Moribund animals showed a spectrum of conditions of which two were most common. The first involved a haemocytic infiltration into the antennal gland tubules and sinuses. Nuclear transformation was common with some reactive hyperplasia and in one case, bright eosinophilic material was being deposited; a precursor to melanization. Within the lumen of the tubules were rounded, structureless objects attached by a stalk to the epithelial cells. These objects became swollen and then detached. Within the sphere, banana shaped secondary cyst formed like those of the genus *Dissodinium*, parasitic dinoflagellates of the Blastodinida (Drebes 1985). Parasitic dinoflagellates were common on wild nauplii stages of prawns and the current case may indicate the method transmission from spawner to larvae. Of the normal histological stains, only gram and silver methenamine were useful for staining the dinophytes. With gram, the primary cysts were neutral but the secondary cysts were unstained which allowed good contrast. The trophont stage stained heavily with silver much like a fungi.

The second condition that was common in moribund *P. merguensis* was changes in the lymphoid organ. The whole organ was mildly hypertrophied. Cellular changes were graded from haemocytic infiltration, nuclear

and cellular transformation with reactive hyperplasia and basophilic darkening of the cytoplasm with a tendency to anaplasia, and some of these areas organized into spheroids which were not located around a central vessel, and lastly vacuolative necrosis of the hyperplastic areas.

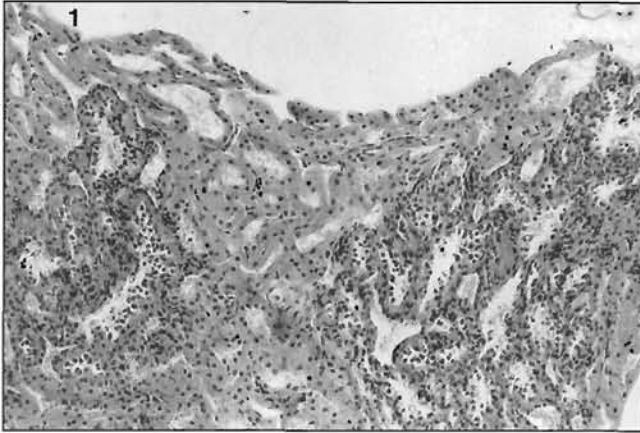


Figure 1. — Cellular infiltrate of antennal gland of *Penaeus merguensis* associated with dinoflagellate infection. $\times 165$.

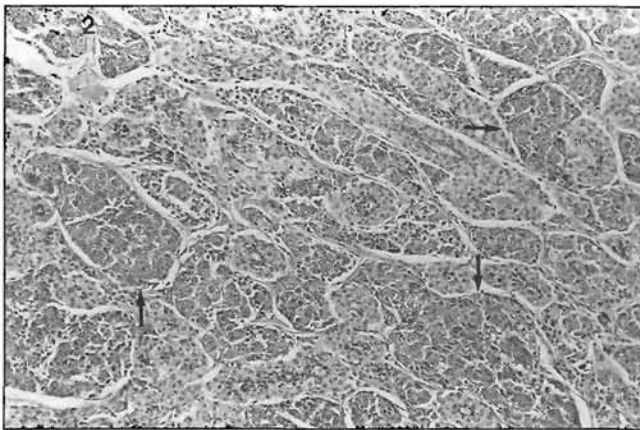


Figure 2. — Areas of cellular and nuclear transformation with tendency to spheroids (arrows) of lymphoid organ of *Penaeus merguensis*. $\times 154$.

Within the transformed areas, basophilic, cytoplasmic inclusions were common and infrequent eosinophilic, intranuclear Cowdrey type A inclusions were in areas with vacuolative necrosis. Both types of inclusions stained with ploxine and not with Macchiavello (inclusion body strains).

One of these cases had diffuse, multifocal necrotic areas within the maxilliped haematopoietic tissue.

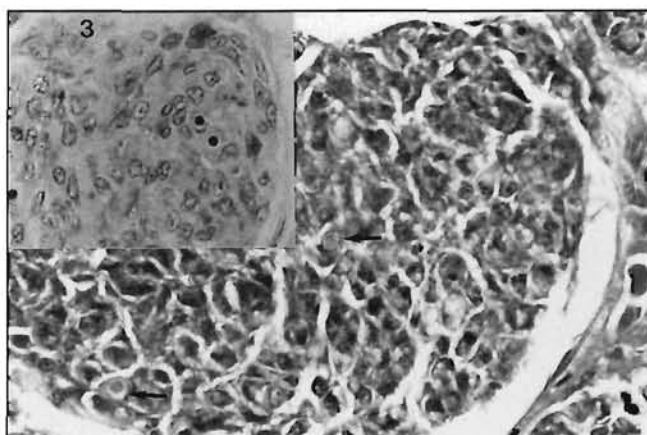


Figure 3. — Insert : Basophilic, cytoplasmic inclusion bodies in the lymphoid organ areas of cellular transformation. $\times 686$. Main figure : Eosinophilic Cowdry's intranuclear inclusion body (arrows) in lymphoid organ spheroid transformation area. $\times 686$.

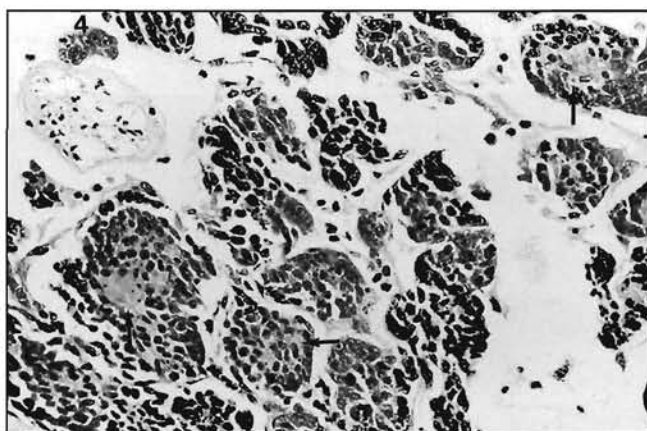


Figure 4. — Maxilliped haematopoietic tissue with diffuse focal eosinophilic necrotic areas (arrows) in *Penaeus merguensis*. $\times 384$.

Large eosinophilic, intranuclear and perinuclear inclusion material was in the ovary of 16 of 81 *Metapenaeus ensis*. The inclusion material first becomes visible as cells passed from the germinal zone, with a single nucleolus and chromatin. The inclusion material was intimately involved with the nucleolus. As the nucleoli split and became multiple around the periphery of the nucleus (Tom et al., 1987), the amount of inclusion material multiplied. No oocytes having inclusion material reached vitellogenic stage 2 (reducing PAS positive) of Tom et al. (1987), suggesting

halted development or dispersion of the inclusion material. Infected cells accumulated in tracts similar to germinal zones and often connected with germinal zones. In ultrathin sections, cells in these tracts were characterized by lack of cell membranes. In heavily infected prawns, the basophilic cytoplasm of immature oocytes also showed weak inclusion material stain. Some infected cells became hypertrophic before rupturing due to the inclusion material.

Other staining characteristics of the inclusion material include being positive for phloxine, pyronin and weakly positive for Ziehl Nielsen (Table 1). The material stained negative with Macchiavello, Feulgen, Methyl-Green, Pas, Giemsa, Luxol fast blue and Herxheimer. The material was unreactive with Gram stains.

These results suggested the material to be RNA (Pyronin) and not DNA (Feulgen, Methyl-Green), lipid (Herxheimer, Luxol), bacteria (Gram), fungi (PAS), rickettsia (Macchiavello, Giemsa) or mycoplasmas (Ziehl Nielsen). With the semi-thin sections cut from the resin blocks, the inclusion material stained with fuchsin and darkly with Toluidine blue.

Tab. 1. — Histochemical characterization of Ovarian Inclusion Material of *Metapenaeus ensis*

Stain	Result	Compound stained for
Paraffin Sections		
Haemotoxylin & eosin	eosinophilic	
Phloxine/Tartrazine	phloxophilic	inclusion bodies, fibrin
Macchiavello	-ve	inclusion bodies, Rickettsiae
Feulgen	-ve	DNA
Methyl Green/Pyronin	+ ve	RNA DNA/RNA
Gram	nonreactive	bacteria
PAS	-ve	fungi, mucins
Giemsa	-ve	Rickettsiae, inclusion, bodies, bacteria
Ziehl Neelsen	weakly + ve	acid fast bacteria, mycoplasm
Luxol fast blue	-ve	myelin, phospholipids, nissl substance
Herxheimer	-ve	lipids
Trichrome (M.S.B.)	+ ve (scarlet red)	inclusion material
Epoxy resin sections		
Toluidine Blue	+ ve	
Fuchsin	fuchsinophilic	

Under the electron microscope, the inclusion material was electron dense and was again perinuclear and intranuclear. Due to the poor fixation procedure, resolution was severely compromised. However, some structures were visible including membranous labyrinths, a net-like proliferation of nuclear membranes associated with inclusion material very similar to

those alter nations caused by *Baculovirus penaei* (Couch, 1974) and *Plebejus baculovirus* (Lester et al., 1988). We have called this syndrome RNA proliferation.

II Larval and Juvenile Prawns

Bright eosinophilic cytoplasmic material was found by Jan Paynter of the University of Queensland in the hepatopancreas of juvenile *Penaeus plebejus* that were grown in water heated by a power station. The material had little structure with very small basophilic speckles. Cells were greatly hypertrophied, the cellular nucleus was displaced to the margin and the hepatopancreas had more vacuolated B-cells than normal. Serial sections revealed early globular stages progressing to an open anastomosing primordium and lastly to many small (5 µm) sporozoites. It is believed to be a type of coccidia as the early stages were similar to poultry coccidia and the production of sporozoites also suggest a coccidia. The stages observed were very similar to the coccidia *Ixories psychropotae* from a holothurian (Massin et al., 1978).

Bungoo or rhinoceros disease was first discovered in mysis of *P. monodon* by Lindsey Trott and Matt Kenway of Australian Institute of Marine Science. The antennae droop or stand upright, wither and become necrotic and can eventually kill the larvae. In juvenile *P. esculentus* it was not fatal but antennae were no more than stubs. The causative agent is a protozoan of unknown affinities. It has been reported in the Philippines and Thailand were the names come from.

Experiments with bacteria of the genus *Vibrio* on protozoa of *P. monodon* by Paul Muir and David Sutton of James Cook University of North Queensland have shown *V. damsela* to be a primary pathogen and caused a septicaemia. The post common change was vacuolation of the ganglionic neuropiles and concurrent shrinkage of the neuropile with *V. damsela* and *V. harveyi*. Fragmentation and loss of the muscle blocks due to coagulative was common with all *Vibrio* spp. but not with *Pseudomonas nautica*. There was atrophy of the hepatopancreas which was most marked in the *V. damsela* and *V. harveyi* treatments. Cuticular necrosis was not seen. In terms of histological change and progressing from mild to severe, the bacterial treatments were ranked as follows : control, *P. nautica*, S.P. *Vibrio*, *V. harveyi* and *V. damsela*.

III Macrobrachium rosenbergii

Little culture of the giant freshwater prawn has been attempted in Australia. However, disease has been a large problem in all such attempts. The first such problem was with the bopyrid *Probopyrus buitendijki*. A hatchery in Darwin was supplying infected postlarvae to grow-out ponds from Atherton Tablelands to the Maroochy River, Queensland, a distance of 3000 km. The unsightly parasite had to be removed manually at the time of marketing and the deformed carapace caused some consumer concern. One facility had a severe recurring problem with microsporidiosis which finally forced the farm to close. The genus of the microsporidian was not determined but the *Thelohania* has been recovered from freshwater crayfish

that cohabit the same areas as *M. rosenbergii*. Mid cycle disease (MCD) has been reported in both north Queensland and Western Australia (Louise Evans, Curtin University of Technology, pers. com.). The hepatopancreatic epithelium showed progressive atrophy and increased vacuolation whilst muscle bundles also atrophied. *Vibrio alginolyticus* was isolated from the animals in north Queensland.

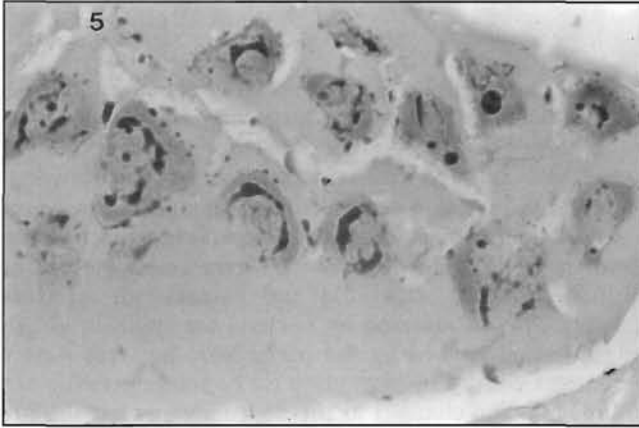


Figure 5. — Intranuclear and perinuclear RNA proliferation in the ovary of *Metapenaeus ensis*. $\times 274$.

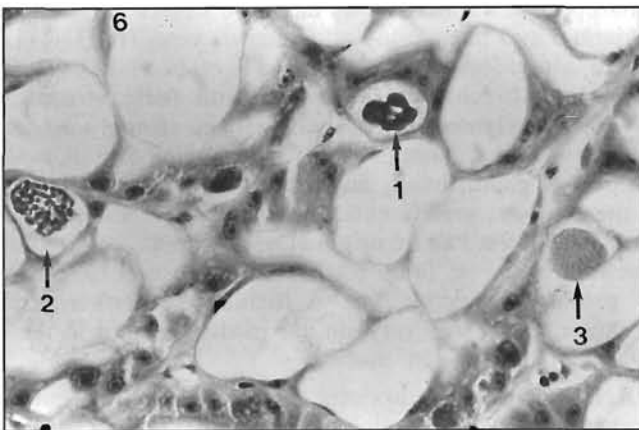


Figure 6. — Coccidian-like organism in the hepatopancreas of *Penaeus plebejus* showing three different stages of development.

1. Primordium.
2. Anastomosing and condensing primordium.
3. Sporozoite formation. $\times 603$.

Ian Anderson of the Queensland Department of Primary Industries Aquaculture Health Program identified large basophilic intranuclear inclusion bodies in hypertrophied hepatocytes of *M. rosenbergii* from farms

in Malaysia. Although electronmicroscopy was not performed, the inclusions were indistinguishable from Hepatopancreatic Parvovirus of penaeids.

DISCUSSION

I Bacteria

Enterobacter aerogenes has been isolated the most frequently from MCD. MCD is characterized by the large amount of coccobacilli found within the lumen of the hepatopancreas (Brock 1988). In the present case *V. alginolyticus* was isolated from freshwater prawns showing signs of MCD. *V. damsela* did cause a septicaemia in penaeid prawn protozoa, in line with studies of *V. alginolyticus*, *V. anguillarum* and *Aeromonas* sp. (Lightner and Lewis 1975). *V. damsela* has been implicated as a pathogen for damsel fish (Love et al., 1981) and barramundi (Glazebrook and Campbell, 1987). Prawns affected by bacteria are typically off-feed. Some of the changes herein caused by the pathogenic bacteria were consistent with those changes caused by starvation (ie hepatopancreatic atrophy and muscle catabolism). The changes to the neuropile suggest the involvement of a neurotoxin.

II Syndromes

Haematopoietic tissue necrosis has been associated with both infectious hypodermal and haematopoietic necrosis virus (IHHN) (Lightner et al., 1983) and Monodon baculovirus (Nash et al., 1988). There was no mention of lymphoid changes associated with these viruses. However, spheroids within the lymphoid organ have been strongly associated with idiopathic generalized inflammation of *P. monodon* and *P. penicillatus* in the gills, antennal gland, heart, and subcuticular tissues (Lightner et al., 1987). All these tissues are attacked by IHHN. IHHN is now believed to be a virus of Indo-West Pacific origin (Lightner, pers. com.) and therefore endemic prawns have a long history of exposure to the virus and noticeably produce Cowdrey type A inclusions. Furthermore body of IHHN (Lightner, 1985) was very similar to those found in the lymphoid organ of *P. merguensis* in the study.

The RNA proliferation is not a normal part of ovarian maturation in *M. ensis* (Yano, 1985). Special histological stains have excluded all infectious agents except viruses as being the cause of the inclusion material. Also, changes seen under TEM resembled changes caused by virus (Couch, 1974, Lightner et al., 1983). Of the seven well known viruses of penaeid prawns only one, IHHNV, attacks mesodermal and ectodermal tissues. All the others, many of the possible viruses (Lightner, 1985) and some environmentally caused inclusion bodies attack endoderm tissue, especially the hepatopancreas. RNA proliferation attacks mesodermal tissue.

Whilst RNA proliferation can be intranuclear, its preferred site appears to be adjacent to the nucleus in the cytoplasm but always

associated with nucleoli. Similarly, late in IHHNV infections, cytoplasmic replication occurs (Lightner, 1985). IHHNV is thought to probably be a picorna virus (RNA virus) (Lightner, 1985) and RNA proliferation, as the name suggest, is positive for RNA.

IHHNV primarily affects juvenile prawns with the numbers of inclusions becoming less as the epizootic progresses. Survivors are thought to be asymptomatic carriers for the rest of their lives. RNA proliferation seems to offer a possible mechanism for the carrier status and spread of the virus to operate besides cannibalism or necrophagia. As RNA proliferation is located in the ovary, spawning will release virions into the environment with eggs so the infection of a new generation of prawns seems assured. However, vertical transmission within the ovary seems unlikely as heavily infected oocytes do not seem to complete vitellogenesis. Possibly, single or low numbers of virions may be incorporated in normal eggs for later activation.

RNA proliferation and IHHNV are similar because (a) both attack mesodermal tissues (b) both produce eosinophilic inclusion bodies first in association with the nucleus and later in association with the cytoplasm (c) IHHNV is thought at present to be a picorna virus (RNA) and the proliferation inclusion material is RNA (d) EM changes were similar to those observed for IHHNV and (e) the inclusion material is located in a site which would be a logical follow on from early epizootic events.

In conclusion, both these above syndromes suggest a IHHN- like virus is present in Australia, but the local prawns have evolved in contact with the virus and may not display the characteristic epizootics and histology.

Acknowledgements. *Special thanks to J. Paynter, L. Trott, M. Kenway, I. Anderson, P. Muir and D. Sutton who all provided material for this study. This research was funded by a James Cook University of North Queensland Special Research Grant and by a Rural Credit Development Fund grant.*

-
- Brock J.A. (1988).** Larval Mid-cycle disease of *M. Rosenbergii*. In: Sindermann, C.J. and Lightner, D.V. (eds.). Disease diagnosis and control in North American marine aquaculture. Developments in Aquaculture and Fisheries Science, 17 : 134-137.
- Burns W.A. and A Bretschneider, (1981).** Thin is in : Plastic embedding of Tissue for Light Microscopy; Educational Products Division, American Society of Clinical Pathologists, Chicago, P18-19.
- Couch J.A. (1974).** An enzootic nuclear polyhedrosis virus of pink shrimp : ultrastructure, prevalence and enhancement. *J. Invertebr. Pathol.*, 24 : 311 - 331.
- Culling C.F.A., R.T Allison and W.T. Barr, (1985).** Cellular Pathology Techniques; 4th Edn, Butterworth, London.
- Drebes G. (1985).** Life cycle and host specificity of marine parasitic dinophytes. In : O. Kinne and H.P. Bulnheim (eds). Diseases of marine organisms. *Helgolander Meeresunters.* 37 : 603 - 622.

- Glazebrook J.S. and R.S.F. Campbell, (1987). Diseases of barramundi (*Lates calcarifer*) in Australia : a review. In : Copland, J.W. and Grey, D.L. (eds) Management of wild and cultured sea bass/barramundi (*Lates calcarifer*) : ACIAR Proc. 20 : 204-206.
- Lester R.J.G., A. Doubrovsky, J.L. Paynter, S.K. Sambhi and J.G. Atherton, (1988). Light and electronmicroscope evidence of baculovirus infection in the prawn *Penaeus plebejus*. *Dis. aquat. Org.*, 3 :217 - 219.
- Lightner D.V. and D.H. Lewis, (1975). A septicemic bacterial disease syndrome of penaeid shrimp. *Mar. Fish. Rev.*, 37 : 25 - 28.
- Lightner D.V., R.M. Redman and T.A. Bell, (1983). Infectious hypodermal and hematopoietic necrosis, a newly recognized virus disease of penaeid shrimp. *J. Invertebr. Pathol.*, 42 : 62 - 70.
- Lightner D.V., (1985). A review of the diseases of cultured penaeid shrimps and prawns with emphasis on recent discoveries and developments. *Proc. First Inter. Conc. Culture Prawns Shrimps. Iloilo City, Philippines 1984* : 79-103.
- Lightner D.V., R.P. Hendrick, J.L. Fryer, S.N. Chen, I.C. Liao and G.H. Kou, (1987). A survey of cultured penaeid shrimp in Taiwan for viral and other important diseases. *Fish Pathology*, 22 : 127 - 140.
- Love, M., D. Teebken-Fisher, J.E. Hose, J.J. Farmer and G.R. Fanning, (1981). *Vibrio damsela*, a marine bacteria, causes skin ulcers on the damsel fish *Chromis punctipinnis*. *Science*, 214 : 1139 - 1140.
- Massin, C., M. Jangoux and M. Sibuet, (1978). Description *D'Ixoreis psychropotae* nov. gen., Nov. sp., coccidie parasite du tube digestif de l'holothurie abyssale *Psychropotes longicauda* Theel. *Protistologica*, 16 : 253 - 259.
- Nash, G., A. Poernomo and M.B. Nash, (1988). Baculovirus infection in brackishwater pond cultured *Penaeus monodon* Fabricius in Indonesia. *Aquaculture*, 73 : 1 - 6.
- Owens, L. and S. Hall-Mendelin, (1989, in press). Diseases relevant to tropical Australian penaeid mariculture. In : T.C. Cheng and F.O. Perkins (eds.). Pathology in Marine Aquaculture. Academic Press. London.
- Tom, M., M. Goren and M. Ovardia, (1987). Localizations of the vitellen and its possible precursors in various organs of *Parapenaeus longirostris* (Crustacea, Decapoda, Penaeidae) *Inter. J. Invertebr. Reprod. Devel.*, 12 : 1 - 12.
- Yano, I. (1985). Induced ovarian maturation and spawning in greasyback shrimp *Metapenaeus ensis*, by progesterone. *Aquaculture*, 47 : 223 - 229.