

# 13

## A review of the known hosts, geographical range and current diagnostic procedures for the virus diseases of cultured penaeid shrimp

D.V. LIGHTNER, T.A. BELL and R.M. REDMAN

Environmental Research Laboratory University of Arizona, 2601 East Airport Drive, TUCSON, AZ 85706 USA

**Abstract** — At least six virus diseases are presently known in cultured penaeid shrimp. Each of these six penaeid virus diseases (BP = *Baculovirus penaei*; MBV = *P. monodon*-type baculovirus (including PBV of Australian penaeids); BMN = baculoviral midgut gland necrosis; HPV = hepatopancreatic parvo-like virus; IHNV = infectious hypodermal and hematopoietic necrosis virus; and REO = reo-like virus of the hepatopancreas) may be comprised by a multitude of individual strains, some of which are highly pathogenic to some penaeids, while being of little importance to others.

BP is widespread in its distribution in cultured and wild penaeids in the Americas, and except for Hawaii, it has not been observed elsewhere. MBV-type baculoviruses have a diverse host range and wide distribution on the Indopacific coasts of Asia, Australia, and Africa and in Southern Europe. Reports of BMN have been confined to *P. japonicus* cultured in Southern Japan. HPV has a geographic range similar to that of MBV in Asia and Australia. IHNV has a world-wide distribution in cultured penaeid shrimp, but its distribution in wild penaeids remains virtually unknown. The only occurrences of IHNV (or a similar agent) in shrimp culture facilities using only wild broodstock have been in Southeast Asia. Little is known about REO, with the only reports of viruses of this type coming from cultured penaeids in France, Malaysia, and Hawaii. Three basic diagnostic procedures are used in screening penaeid shrimp stocks for virus infections :

- 1) direct samples for microscopic (wet-mount) examination or histopathology for signs of virus infection (e.g. polyhedral occlusion bodies);
- 2) enhancement of infection by severe crowding « stress » followed by microscopic examination or histopathology;
- 3) bioassay of a suspect shrimp population with a sensitive indicator species followed by sampling and histopathology; more rapid and sensitive advanced diagnostic procedures based on serological and gene probe technologies are being developed, but are not yet available to the industry.

## INTRODUCTION

Six virus diseases are presently recognized in the penaeid shrimp (Table 1). These six viruses are : BP = *Baculovirus penaei* (Couch, 1974); MBV = *P. monodon*-type baculovirus (Lightner and Redman 1981); BMN = baculoviral midgut gland necrosis (Sano et al., 1981); IHNV = infectious hypodermal and hematopoietic necrosis virus (Lightner et al., 1983a); HPV = hepatopancreatic parvo-like virus (Lightner and Redman, 1985); and REO = reo-like virus (also known as RLV) of the hepatopancreas (Tsing and Bonami, 1987) (Fig. 1). Each virus may actually comprise a multitude of individual strains, some of which are

Tab. 1. — The known penaeid viruses

Virus	Virion Size	Approximate Nucleic Acid	Probable Classification
IHNV	20 nm	ssRNA (?)	Picornavirus (?)
HPV	22 nm	ssDNA (?)	Parvovirus
REO	60 nm	dsRNA	Reo-like virus
BP	~ 75 × 300 nm	dsDNA	Baculovirus; occluded
MBV	~ 75 × 300 nm	dsDNA	Baculovirus; occluded
BMN	~ 75 × 300 nm	dsDNA	Baculovirus; non-occluded

IHNV = Infectious hypodermal and hematopoietic necrosis virus

HPV = Hepatopancreatic parvo-like virus

REO = Reo-like virus

BP = *Baculovirus penaei*

MBV = *P. monodon*-type baculoviruses

BMN = Baculoviral mid-gut gland necrosis

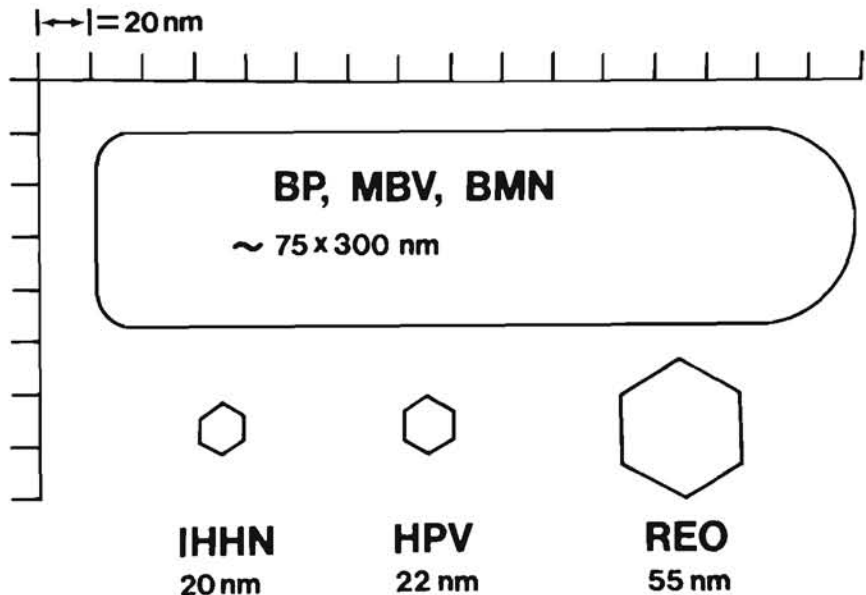


Figure 1. — A schematic representation of the six known viruses. All are shown in relative size.

highly pathogenic to some penaeids, while being of little consequence to other penaeids (Table 2). In this review *Plebejus Baculovirus* (PBV) of Australian *P. plebejus* (Lester et al., 1987; Doubrovsky et al., 1988) is considered to be an MBV-type baculovirus.

Tab. 2. — The penaeid viruses and their natural and experimentally infected hosts

Host Subgenus And Species**	VIRUS*					
	BP	MBV	BMN	IHHNV	HPV	REO
<i>Litopenaeus</i>						
<i>P. vannamei</i>	+++	+		+	+	
<i>P. stylirostris</i>	++			+++		
<i>P. setiferus</i>	+			+(e)		
<i>P. schmitti</i>	++					
<i>Penaeus</i>						
<i>P. monodon</i>	+	++		++	++	++
<i>P. esculentus</i>		+			++	
<i>P. semisulcatus</i>		+		+	+++	
<i>Fenneropenaeus</i>						
<i>P. merguensis</i>		++			+++	
<i>P. indicus</i>					++	
<i>P. chinensis</i> (= <i>orientalis</i> )					++	
<i>P. penicillatus</i>	++	++			++	
<i>Marsupenaeus</i>						
<i>P. japonicus</i>			+++	++(e)		+++
<i>P. plebejus</i>		++				
<i>Farfantepenaeus</i>						
<i>P. aztecus</i>	+++			+(e)		
<i>P. duorarum</i>	+++			+(e)		
<i>P. brasiliensis</i>	++					
<i>P. paulensis</i>	++					
<i>P. subtilis</i>	++					
<i>Melicertus</i>						
<i>P. kerathurus</i>		+				
<i>P. marginatus</i>	+++					
<i>P. plebejus</i>		++				

\* Abbreviations

BP = *Baculovirus penaei*

MBV = *P. monodon*-type baculoviruses

BMN = Baculoviral mid-gut gland necrosis

IHHNV = Infectious hypodermal and hematopoietic necrosis virus

HPV = Hepatopancreatic parvo-like virus

REO = Reo-like virus

+ = Infection observed, but without signs of disease

++ = Infection may result in moderate disease and mortality

+++ = Infection usually results in serious epizootic

e = Experimentally infected; natural infections not yet observed

\*\* Classification according to Holthuis, 1980, FAO Species Catalog.

## DIAGNOSTIC PROCEDURES

Three basic diagnostic procedures are currently in use to screen penaeid shrimp for virus infections :

- 1) Direct samples for microscopic (wet-mount) examination and/or histopathology or electron microscopy.
- 2) Enhancement of infection followed by sampling and histopathology and electron microscopy.
- 3) Bioassay of a suspect shrimp population with a sensitive indicator species combined with direct sampling and examination of the indicator shrimp for signs of infection using wet-mounts or histopathology.

### Direct Diagnostic Procedures

Random or (preferably) nonrandom samples of shrimp, or shrimp feces, are selected in the direct sampling procedure from culture tanks, ponds, or cages and examined directly for signs of BP or MBV in wet-mounts, or they may be preserved in Davidson's AFA or in 10% buffered formalin (Humason, 1967) for histological evaluation. The sensitivity of this procedure is limited, and it will only demonstrate shrimp with viral infections that are acute or subacute in a population with a high incidence rate. All six types of penaeid virus infections (IHHN, REO, BP, MBV, BMN, and HPV) may be diagnosed successfully with direct samples, but such samples have also produced false negative diagnoses on populations later shown by electron microscopy, enhancement, or bioassay diagnostic procedures to be positive for one of these virus diseases.

### Enhancement Diagnostic Procedures

A quarantined population in the enhancement procedure is reared under relatively crowded and stressful conditions. Post-larvae are best used for this test, which normally requires 30 to 60 days. Random samples are taken at intervals throughout the test period, or moribund animals are nonrandomly sampled when they are observed. Samples may be prepared for direct wet-mount microscopic examination for occlusion bodies diagnostic of BP and MBV-caused diseases, or for histology for diagnosis of IHHN disease in *P. stylirostris*, *P. vannamei*, and *P. monodon*. Demonstration of unapparent infections due to HPV and REO may also be possible by the enhancement procedure. Enhancement is not a suitable procedure for demonstration of IHHNV in asymptomatic carriers (i.e. subadult or adult *P. stylirostris* IHHN epizootic survivors, or in species such as *P. vannamei* which are readily infected by the virus, but seldom show diagnosable infection after the early juvenile stages).

### Bioassay Diagnostic Procedures

Carriers of IHNV may be detected by bioassay with sensitive « indicator » shrimp. Indicator shrimp in this procedure (juvenile *P. stylirostris* of 0.05 to 4 g body weight) may be exposed to samples of suspect carrier shrimp by one or more of three methods.

- 1) Injection with a cell-free filtrate prepared from a homogenate of suspect carrier shrimp (the indicator shrimp will show signs of IHNV disease within 5 to 15 days if the suspect shrimp were infected with IHNV).
- 2) Rearing in the same tank suspect carrier shrimp with indicator shrimp (the indicator shrimp will show signs of IHNV disease within 30 to 60 days).
- 3) Feeding minced carcasses of suspect carrier shrimp to indicator shrimp (the indicator shrimp will show signs of IHNV within 15 to 30 days).

In actual bioassay tests, the latter technique of exposure (i.e. feeding carcass fragments to the indicator shrimp) has become the method of choice.

### Current Disease Specific Procedures

Actual diagnosis of infection by BP, MBV, HPV, IHNV, and REO is dependent on microscopic or histologic demonstration of the particular cytopathology that is unique to each disease. Gross signs and behavior are usually not sufficiently specific in shrimp with infection by these penaeid viruses to be used reliably in diagnosing these diseases.

### BP and MBV

Patent acute BP and MBV infections may be readily diagnosed by demonstration of their characteristic occlusion bodies in either wet-mounts of feces, hepatopancreas, or midgut, or in histological preparations of the latter two organs. BP occlusions are distinctive tetrahedral bodies (Couch, 1974, 1981) easily detected by bright field or phase microscopy in unstained wet-mounts of feces or tissue squashes while MBV occlusions are spherical and therefore difficult to distinguish from lipid droplets, secretory granules, etc. The use of a stain, like 0.05 % aqueous malachite green, in preparing wet mounts for MBV diagnosis aids in demonstration of the occlusion bodies (Lightner *et al.*, 1983c). Presumably, the protein making up the occlusion absorbs the stain more rapidly than does most other material in the feces or in host tissues, contrasting them relative to other materials present within a few minutes.

BP and MBV occlusion bodies in histological preparations appear as prominent eosinophilic (with H & E) usually multiple inclusion bodies within the hypertrophied nuclei of hepatopancreatic tubule or midgut epithelial cells. Often the affected nuclei have a peripherally displaced compressed nucleolus and marginated chromatin, giving affected nuclei a « signet ring » appearance even before occlusion bodies become well developed. Brown and Brenn histologic Gram stain (Luna, 1968), although not specific for baculovirus occlusion bodies, tends to stain occlusions

more intensely (either red or purple, depending upon section thickness, time of decolorization, etc...) than the surrounding tissue, aiding in demonstrating their presence in low-grade infections.

Transmission electron microscopy of BP and MBV infected cells show large numbers of rod-shaped baculovirus particles both free and occluded within the protein matrix of the occlusion body.

### BMN

BMN affects the same target organs as does BP and MBV, but unlike BP and MBV it does not produce an occlusion body. Hence, its diagnosis is dependent upon history, clinical signs, and on wet-mount observations and histopathology of the hepatopancreas. Sano *et al.* (1984) in Japan have also reported development of a fluorescent antibody diagnostic technique for BMN. By wet-mount microscopy or histology the principal diagnostic feature of BMN is hypertrophied nuclei within infected hepatopancreatocytes (Sano *et al.*, 1981 and Momoyama, 1983). These enlarged nuclei have margined chromatin, a laterally displaced or disassociated nucleolus, but lack occlusion bodies.

### HPV

Diagnosis of HPV is dependent upon the histological demonstration of single prominent basophilic (with H & E), Feulgen positive (Luna, 1968) intranuclear inclusion bodies in the hypertrophied nuclei of infected hepatopancreatic tubule epithelial cells. Consequent lateral displacement and compression of the nucleolus and chromatin margination are also prominent features of such infected cell nuclei. Early in their development, HPV inclusions are small eosinophilic bodies centrally located within the nucleus and closely associated with the nucleolus.

TEM of HPV-infected hepatopancreatocytes shows the inclusion body to contain virus-like particles of 22 to 24 nm in diameter. HPV is presumed to be a parvovirus because of its size, its Feulgen reaction, and its host cell cytopathology, that are quite similar to the reported characteristics of the parvovirus group (Kurstak *et al.*, 1977; Longworth, 1978; and Paradiso *et al.*, 1982).

### IHHNV

Diagnosis of infection by IHHNV is dependent upon histological demonstration of prominent eosinophilic (with H & E), Feulgen negative intranuclear inclusion bodies within chromatin margined, hypertrophied nuclei of cells in tissues of ectodermal (epidermis, hypodermal epithelium of fore and hindgut, nerve cord, and nerve ganglia) and mesodermal origin (hematopoietic organs, antennal gland tubule epithelium, connective tissue, and striated muscle). Usually the midgut, midgut ceca, and the hepatopancreas (endoderm-derived tissues) are unaffected, except in severe cases where hepatopancreatic involvement has been observed (Lightner *et al.*, 1985). These inclusions match closely the characteristics

Tab. 3. — Natural and introduced geographic distribution of the penaeid viruses

Virus	Distribution in Wild Penaeids	Introduced Distribution
BP	Americas : Atlantic side; from SE U.S., Gulf of Mexico, Caribbean into Brazil Pacific side; from Peru and Ecuador through Central America into Mexico Hawaii	No major introductions
MBV	IndoPacific : P.R. China, Taiwan, Philippines, Malaysia, Singapore, Thailand, Sri Lanka, Indonesia Australia Africa : S. Africa Middle East : Israel, Kuwait Mediterranean : Italy	Pacific : Tahiti, Hawaii Americas : Mexico, Ecuador, Brazil, SE U.S.
BMN	Asia : Japan	
HPV	IndoPacific : P.R. China, Taiwan, Philippines, Malaysia, Singapore, Indonesia Australia Africa : Kenya Middle East : Israel, Kuwait	Americas : Brazil, Ecuador Pacific : Hawaii
IHHNV	Asia : Malaysia, Indonesia, Philippines, Singapore	Americas : SE U.S., Caribbean, Brazil, Venezuela, Ecuador, Peru, Central America Pacific : Hawaii, Guam, Tahiti Asia : Taiwan Middle East : Israel
REO	Asia : Japan, Malaysia	Pacific : Hawaii Europe : France

of the type A intranuclear inclusion body class described by Cowdry (1934). Basophilic chromatin strands are occasionally visible by light microscopy within IHHN intranuclear inclusion bodies. These chromatin strands are a prominent feature of IHHN intranuclear inclusion bodies by TEM.

IHHN intranuclear inclusion bodies are common early in acute infections, later decreasing in number, and are followed by necrosis and inflammation of target tissues. Affected cells may also have highly vacuolated cytoplasm with cytoplasmic bodies that range from eosinophilic to basophilic. Although the prominent intranuclear inclusions present in shrimp infected with IHHNV are evidence of nuclear involvement, assembly of the virus occurs in the cytoplasm of affected cells. The size and morphology of the virus, 17 to 26 nm in sections and 20 nm in

purified preparations, and its replication within the cytoplasm support the tentative classification of IHNV with the picornaviruses.

## REO

Diagnosis of REO at present is dependent upon gross signs and demonstration by electron microscopy of large cytoplasmic inclusions containing 50 to 70 nm diameter virus particles in the cytoplasm of F-cells and R-cells of the hepatopancreatic tubule epithelium. The non-enveloped, icosahedral virions of REO measure about 60 nm and 50 to 70 nm in diameter, respectively, in purified preparations and in tissue sections. In all species in which REO has been recognized, REO lesions in the hepatopancreas are usually eosinophilic, but not readily apparent. Hence, most infections are overlooked until found by electron microscopy (Tsing and Bonami, 1987; Lightner, 1988).

## HOSTS AND GEOGRAPHIC DISTRIBUTION

The host geographic range of the known penaeid viruses has been updated several times recently (Couch, 1981; Johnson, 1983; Lightner, 1983; Lightner et al., 1985; and Lightner, 1988). Surveys and investigations of mortality problems undertaken by the authors' laboratory and other research groups in various shrimp growing areas have provided new data on several of the virus diseases that affect cultured penaeid shrimp. This review of the penaeid viruses emphasizes the current diagnostic procedures for the penaeid viruses, their natural hosts, and their natural and introduced geographic distributions.

## BP

BP is widely distributed in cultured and wild penaeids in the Americas, ranging from the Northern Gulf of Mexico south through the Caribbean and reaching at least as far as the State of Bahia in central Brazil. On the Pacific Coast, BP ranges from Peru to Mexico, and it has been observed in wild penaeid shrimp in Hawaii. BP has not yet been observed in wild, cultured or imported (from the Americas) penaeids outside of the Americas. Recent new information on the host and geographic distribution of BP has come from Brazil and Mexico. In South America (Ecuador and Brazil), BP was found to infect larvae and post-larvae of six penaeid species. In Ecuador BP was found to infect imported larval *P. monodon* in a hatchery in which BP was enzootic in its stocks of *P. vannamei* (Philippe Danigo, pers. com., December 19, 1984, SEMACUA, Ecuador). BP has been found in at least two hatcheries in Brazil in native *P. schmitti*, *P. paulensis*, and *P. subtilis*, and in introduced *Penaeus vannamei* and *P. penicillatus*. Five of these species (all but *P. vannamei*) represent new host species for the virus (Table 3). BP was found for the first time in Mexico in cultured larval and post larval *P. stylirostris* at a facility near Guaymas, Sonora on the West Coast of Mexico (Lightner et al., 1988). Because the affected facility had no history



of stock importations, BP must be assumed to be enzootic in wild penaeids in the region.

### MBV

MBV-type baculoviruses are similar to BP in their diverse host range and in their wide distribution on the IndoPacific coasts of Asia, Australia, and Africa, and in Southern Europe. However, unlike BP, MBV has been observed in the Americas in imported stocks and in an American penaeid exposed to the virus. Although MBV was first discovered in a quarantined population of *P. monodon* that had originated from Taiwan (Lightner and Redman, 1981; Lightner et al., 1983c), it had not actually been demonstrated in Taiwan until it was found to be widely distributed in Taiwanese shrimp farms in a 1986 survey of the country (Lightner et al., 1987). Studies in 1987 linked MBV to serious disease losses in many Taiwanese farms (S.N. Chen and G.H. Kou, unpublished communication, National Taiwan Univ., Taiwan).

Since the information on MBV was last summarized, MBV has been found in Texas, Ecuador, and Brazil in imported stocks of *P. monodon*. Of possible significance in Ecuador was the presence of MBV-like (spherical) occlusion bodies found along with a heavy BP infection of juvenile *P. vannamei* being cultured with MBV-infected *P. monodon*.

A similar agent, found first in *P. plebejus* and thus called *P. plebejus* baculovirus (PBV), was found in cultured penaeids in Australia (Lester et al., 1987). A similar baculovirus was also found in Australian *P. monodon* and *P. merguensis* (Doubrovsky et al., 1988). Other than its presence in a new host species, the agent of PBV differs little from MBV in host cell cytopathology and in the morphology of the virus, and it may represent a strain of the MBV-type viruses rather than a separate distinct species.

### BMN

BMN has been reported only in *P. japonicus* cultured in Japan, where it is considered a major problem in the larval and early postlarval stages of that species (Sano et al., 1984, 1985; Sano and Fukuda, 1987). Despite numerous introductions of *P. japonicus* stocks (larvae, postlarvae, and broodstock) to Hawaii, France, Brazil, and other locations during the past two decades, BMN has not been detected in that species or in other penaeids cultured in the Americas.

### HPV

HPV has a geographic range in Asia and Australia similar to that of MBV, and like MBV it has been introduced to the Americas with imported penaeids. More recently, HPV was found for the first time in dual infections with MBV. It was found in post larval and juvenile *P. monodon* sampled from farms in the Pingtung area of Southern Taiwan. This region in 1987 had experienced serious disease losses in its farms due, at least in part, to MBV. The severity of HPV infections in some of the shrimp

sampled suggests that HPV, while unrecognized, may have contributed to the 1987 epizootic.

Reports of HPV in captive-wild *P. esculentus* in Australia (Paynter et al., 1985), in *P. monodon* imported to Israel from Kenya (Colorni et al., 1987), and in captive-wild and hatchery reared *P. indicus* and *P. merguensis* in Singapore (Chong and Loh, 1984) have expanded the known host and geographic distribution of this virus (Tables 2 and 3). In the Singapore study, of four shrimp farms surveyed, HPV incidence was highest (> 50%) in the two farms that reared hatchery-derived post-larvae, and lower (< 15%) in the two farms which cultured only feral shrimp collected by tidal entrapment (Chong and Loh, 1984). This suggests that HPV is transmitted either vertically from parent broodstock, or horizontally from shrimp to shrimp with efficiency only during the larval stages.

HPV has been observed in the Americas. In Brazil in 1987, HPV was found in stocks of *P. penicillatus* imported from Taiwan. At the same culture facility, HPV was found in light infections in juvenile *P. vannamei*, which had been exposed to infected *P. penicillatus* indirectly as a result of normal farming practises. The discovery of HPV in cultured shrimp in Brazil represents the first time this pathogen has been documented in the Americas and in an american penaeid (S. Bueno, R. Meyer, and D. Lightner, unpublished observations). More recently, HPV lesions have been found in *P. vannamei* cultured in Ecuador (Bell and Lightner, unpublished data). The numerous introductions of *P. monodon* from Southeast Asia into Ecuador may have been the source of HPV.

## IHHNV

IHHNV has a world-wide distribution in cultured penaeid shrimp, but its distribution in wild penaeids remains virtually unknown. Infection by the virus causes serious disease in *P. stylirostris*, and acute catastrophic epizootics in intensively cultured juveniles of that species. In other penaeids, IHHNV has been reported to cause infection and disease (Brock et al., 1983; Lightner et al., 1985; and Lightner, 1988), but disease severity does not approach that observed in *P. stylirostris*.

The natural host(s) and natural geographic distribution of IHHNV is largely unknown. However, the occurrence in Southeast Asia (Singapore, Malaysia, Indonesia, and the Philippines) of IHHNV (or a similar agent) in shrimp culture facilities using only wild *P. monodon* broodstock suggests that this region is within the virus' natural geographic range, and that *P. monodon* may be among its natural host species.

Since 1985, no new hosts for IHHNV have been demonstrated. However, the geographic distribution of the virus in culture facilities has continued to expand. In Mexico in 1987, IHHNV was found in an imported population of post-larval *P. vannamei* at a facility in Baja California (Lightner, unpublished data). Likewise, IHHNV was found to be present in imported quarantined stocks of *P. vannamei* in a 1986 survey of Taiwanese shrimp culture facilities, but not in cultured stocks of other penaeid species, including *P. monodon*, at the farms surveyed (Lightner et al., 1987).

## REO

REO is the newest of the penaeid viruses. It was discovered in 1984 by Tsing and Bonami (1987) in juvenile *P. japonicus* in France using electron microscopy, and subsequently, in the same species in Hawaii using the same technique (Lightner et al., 1985). In related work Tsing et al. (1985) suggested a possible link between infection by REO and « gut and nerve syndrome » (GNS), an idiopathic condition found in chronically ill populations of *P. japonicus* cultured in Hawaii (Lightner et al., 1984). Most recently REO, or a closely related form, has been found associated with a serious disease syndrome in pond-cultured *P. monodon* in Southeast Asia (Nash and Nash, « in press »).

## DISCUSSION AND CONCLUSION

The present diagnostic procedures for the penaeid virus diseases are largely dependent upon history, clinical signs, and histopathology. Electron microscopy is also of importance in some diagnostic applications. Techniques like enhancement and animal bioassays when coupled to histopathology add sensitivity to these diagnostic procedures.

These procedures, however, are very limited. Examination of relatively small samples is one important limitation; the length of time required to carry out routine histopathology and/or electron microscopy is another factor limiting their practical usefulness. Also, the cost of histopathology, electron microscopy, of maintaining enhancement and bioassay areas, and the limited availability of specific pathogen-free indicator shrimp for bioassays, all add to the list of reasons why better, more rapid, more sensitive diagnostic procedures are needed. Methods using tissue culture, serologic methods, and gene probe diagnostic techniques that have become common place in human and veterinary medicine, are being developed for penaeid shrimp. For example, the first documented success at producing primary cell cultures from shrimp was recently reported (Chen et al., 1986). However, while development of these techniques for use with shrimp is underway, none are yet routinely available to the diagnostic labs of the industry. As the new diagnostic methods do become available, they should provide more rapid diagnoses than do current methods; they should be very sensitive and easily standardized among various labs that use them; and they should be inexpensive and simple to run.

The practise of transporting penaeid stocks between facilities and/or different geographic regions has resulted in the introduction of five of the six known penaeid shrimp viruses to regions where they may not have previously existed. Four of the six known types of penaeid viruses are apparently not native to the Americas, but of these four, three (IHHNV, MBV, and HPV) have been introduced with shrimp intended for aquaculture. Whether or not these introduced viruses have escaped the culture facilities to which they have been introduced and have become established in local wild penaeid stocks is not known.

Evaluation of non-native penaeids by the rapidly growing shrimp culture industry is an essential component to the future growth and

development of that industry. Introduction of pathogens like IHHNV to regions where it previously did not occur can have catastrophic consequences to the industry (Lightner et al., 1983a, 1983b; Lightner, 1988). Prevention of such exotic pathogen introduction is dependent upon the use of quarantine, certification and inspection policies, and procedures that are supported by reliable diagnostic tests. Mechanisms have been proposed by a number of international groups to reduce the risks of importation of exotic pathogens and pests with transfers of aquatic species. One example (Sindermann, 1988) entitled, « Revised Code of Practice to Reduce the Risks of Adverse Effects Arising from Introduction of Non-indigenous Marine Species », was adopted in 1979 by the member countries of the International Council for the Exploration of the Sea. The practises outlined in this code, if practised, are effective for their intended purpose. Adoption and implementation of such a policy by the penaeid shrimp aquaculture industry of the Americas may be in the best interest of that emerging industry.

**Acknowledgements.** Grant support for this work was from the U.S.D.A. Cooperative State Research Service; from Sea Grant, U.S. Dept. of Commerce; and from the Hawaii Aquaculture Development Programme.

- 
- Brock J.A., D.V. Lightner, and T.A. Bell, 1983.** A review of four virus (BP, MBV, BMN and IHHNV) diseases of penaeid shrimp with particular references to clinical significance, diagnosis and control in shrimp aquaculture. International Council for the Exploration of the Sea. C.M. 1983/Gen : 10/Mini-Symposium.
- Chen S.N., S.C. Chi, G.H. Kou, and I.C. Liao., 1986.** Cell culture from tissues of grass prawn, *Penaeus monodon*. *Fish Pathology*, **21** : 161 - 166.
- Chong Y.C., and H. Loh, 1984.** Hepatopancreas chlamydial and parvoviral infections of farmed marine prawns in Singapore. *Singapore Veterinary Journal*, **9** : 51 - 56.
- Colorni A., T. Samocha, and B. Colorni, 1987.** Pathogenic viruses introduced into Israeli mariculture systems by imported penaeid shrimp. *Bamidgeh*, **39** : 21 - 28.
- Couch J.A., 1974.** An enzootic nuclear polyhedrosis virus of pink shrimp : ultrastructure, prevalence, and enhancement. *Journal of Invertebrate Pathology*, **24** : 311 - 331.
- Couch J.A., 1981.** Viral Diseases of Invertebrates Other Than Insects. pp. 127-160. In : E.W. Davidson (ed.), Pathogenesis of Invertebrate Microbial Diseases. Allanheld, Osmun Publ., Totowa, N.J.
- Cowdry E.V., 1934.** The problem of intranuclear inclusions in virus diseases. *Archives of Pathology*, **18** : 527 - 542.
- Doubrovsky A., J.L. Paynter, S.K. Sambhi, J.G. Atherton, and R.J.G. Lester, 1988.** Observations on the ultrastructure of baculovirus in Australian *Penaeus monodon* and *Penaeus merguensis*. *Aust. J. Marine Freshwater Res.*, **39** : \*\*\*\*.
- Humason G.L., 1967.** Animal Tissue Techniques. W.H. Freeman and Co., San Francisco, CA. p. 432.

- Johnson P.T., 1983.** Diseases caused by viruses, rickettsiae, bacteria, and fungi. pp. 1-78. In : A.J. Provenzano, Jr. (ed.), *The Biology of Crustacea*, Vol. 6. Academic Press, N.Y.
- Kurstak E., P. Tijssen, and S. Garzon, 1977.** Densonucleosis viruses (Parvoviridae). pp. 67-91. In : Karl Maramorosch (ed.), *The Atlas of Insect and Plant Viruses*. Academic Press, N.Y.
- Lester R.J.G., A. Doubrovsky, J.L. Paynter, S.K. Sambhi, and J.G. Atherton, 1987.** Light and electron microscope evidence of baculovirus infection in the prawn *Penaeus plebejus*. *Diseases of Aquatic Organisms*, **3** : 217 - 219.
- Lightner D.V., and R.M. Redman, 1981.** A baculovirus-caused disease of the penaeid shrimp, *Penaeus monodon*. *Journal of Invertebrate Pathology*, **38** : 299 - 302.
- Lightner D.V., 1983.** Diseases of Cultured Penaeid Shrimp. pp. 289-320. In : J.P. McVey (ed.), *CRC Handbook of Mariculture*. Vol. 1. Crustacean Aquaculture. CRC Press, Boca Raton, FL.
- Lightner D.V., R.M. Redman, and T.A. Bell, 1983a.** Infectious hypodermal and hematopoietic necrosis (IHNN), a newly recognized virus disease of penaeid shrimp. *Journal of Invertebrate Pathology*, **42** : 62 - 70.
- Lightner D.V., R.M. Redman, T.A. Bell, and J.A. Brock, 1983b.** Detection of IHNN virus in *Penaeus stylirostris* and *P. vannamei* imported into Hawaii. *Journal of the World Mariculture Society*, **14** : 212 - 225.
- Lightner D.V., R.M. Redman, and T.A. Bell, 1983c.** Observations on the geographic distribution, pathogenesis and morphology of the baculovirus from *Penaeus monodon* Fabricius. *Aquaculture*, **32** : 209 - 233.
- Lightner D.V., R.M. Redman, T.A. Bell, and J.A. Brock, 1984.** An idiopathic proliferative disease syndrome of the mid-gut and ventral nerve in the Kuruma prawn, *Penaeus japonicus* Bate, cultured in Hawaii. *Journal of Fish Diseases*, **7** : 183 - 191.
- Lightner D.V. and R.M. Redman, 1985.** A parvo-like virus disease of penaeid shrimp. *Journal of Invertebrate Pathology*, **45** : 47 - 53.
- Lightner D.V., R.M. Redman, R.R. Williams, L.L. Mohny, J.P.M. Clerx, T.A. Bell, and J.A. Brock, 1985.** Recent advances in penaeid virus disease investigations. *Journal of the World Mariculture Society*, **16** : 267 - 274.
- Lightner D.V., R.P. Hedrick, J.L. Fryer, S.N. Chen, I.C. Liao, and G.H. Kou, 1987.** A survey of cultured penaeid shrimp in Taiwan for viral and other important diseases. *Fish Pathology*, **22** : 127 - 140.
- Lightner D.V., 1988.** Diseases of cultured penaeid shrimp and prawns. pp. 8-127. In : C.J. Sindermann and D.V. Lightner (eds.), *Disease Diagnosis and Control in North American Marine Aquaculture*. Elsevier, Amsterdam.
- Lightner D.V., R.M. Redman, and E.A. Almada Ruiz, 1988.** *Baculovirus penaei* in *Penaeus stylirostris* (Crustacea : Decapoda) cultured in Mexico : unique cytopathology and a new geographic record. *Journal of Invertebrate Pathology*, **51** : 137 - 139.
- Longworth J.F., 1978.** Small isometric viruses of invertebrates. *Advances in Virus Research*, **23** : 103 - 157.
- Luna L.G. (ed.), 1968.** *Manual of Histologic Staining Methods of the Armed Forces Institute of Pathology*. McGraw-Hill Book Co. N.Y. 259 p.
- Momoyama K., 1983.** Studies on baculoviral mid-gut gland necrosis of Kuruma shrimp (*Penaeus japonicus*) - III. Presumptive diagnostic techniques. *Fish Pathology*, **17** : 263 - 268.
- Nash M., and G. Nash.** « In Press ». A reo-like virus observed in the tiger prawn, *Penaeus monodon*, from Malaysia. *Journal of Fish Diseases*.

- Paradiso P.R., S.L. Rhode, III, and I.I. Singer, 1982.** *Canine parvovirus* : a biochemical and ultrastructural characterization. *Journal of General Virology*, **62** : 113 - 125.
- Paynter J.L., D.V. Lightner, and R.J.G. Lester, 1985.** Prawn virus from juvenile *Penaeus esculentus*, p. 61-64. *In* : P.C. Rothlisberg, B.J. Hill and D.J. Staples (eds.), Second Australian National Prawn Seminar, NPS2, Cleveland, Australia.
- Sano T., T. Nishimura, K. Oguma, K. Momoyama, and N. Takeno, 1981.** Baculovirus infection of cultured Kuruma shrimp *Penaeus japonicus* in Japan. *Fish Pathology*, **15** : 185 - 191.
- Sano T., T. Nishimura, H. Fukuda, T. Hayashida, and K. Momoyama, 1984.** Baculoviral mid-gut gland necrosis (BMN) of kuruma shrimp (*Penaeus japonicus*) larvae in Japanese intensive culture systems. *Helgolander Meeresunters*, **37** : 255 - 264.
- Sano T., T. Nishimura, H. Fukuda, T. Hayashida, and K. Momoyama, 1985.** Baculoviral infectivity trials on kuruma shrimp larvae, *Penaeus japonicus*, of different ages. p. 397-403. *In* : Fish and Shellfish Pathology, Academic Press, N.Y.
- Sano T., and H. Fukuda, 1987.** Principal microbial diseases of mariculture in Japan. *Aquaculture*, **67** : 59 - 69.
- Sindermann C.J., 1988.** Disease problems caused by introduced species. pp. 394-398. *In* : C.J. Sindermann and D.V. Lightner (eds.), Disease Diagnosis and Control in North American Marine Aquaculture. Elsevier, Amsterdam.
- Tsing A., and J.R. Bonami, 1987.** A new viral disease of the shrimp, *Penaeus japonicus* Bate. *Journal of Fish Diseases*, **10** : 139 - 141.
- Tsing A., D. Lightner, J.R. Bonami, and R. Redman, 1985.** Is « gut and nerve syndrome » (GNS) of viral origin in the tiger shrimp *Penaeus japonicus* Bate, p. 91. *In* : Programme and Abstracts of the 2nd International Conference of the European Association of Fish Pathologists. Montpellier, France.