

Histological study of a cellular reaction in *Ruditapes decussatus* infected by a protozoan

DOMINIQUE CHAGOT¹, MICHEL COMPS², VIVIANE BOULO¹, FRANCISCO RUANO³
and HENRI GRIZEL¹

¹IFREMER, LPGIM, Ronce les Bains, 17390 La Tremblade (France)

²IFREMER, 1 rue Jean Vilar, 34200 Sète (France)

³INIP, Avenida de Brasilia, 1400 Lisbon (Portugal)

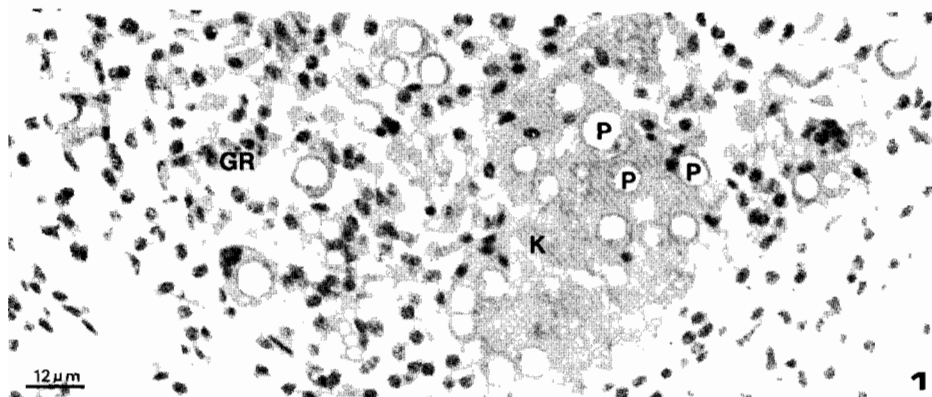
(Accepted 19 March 1987)

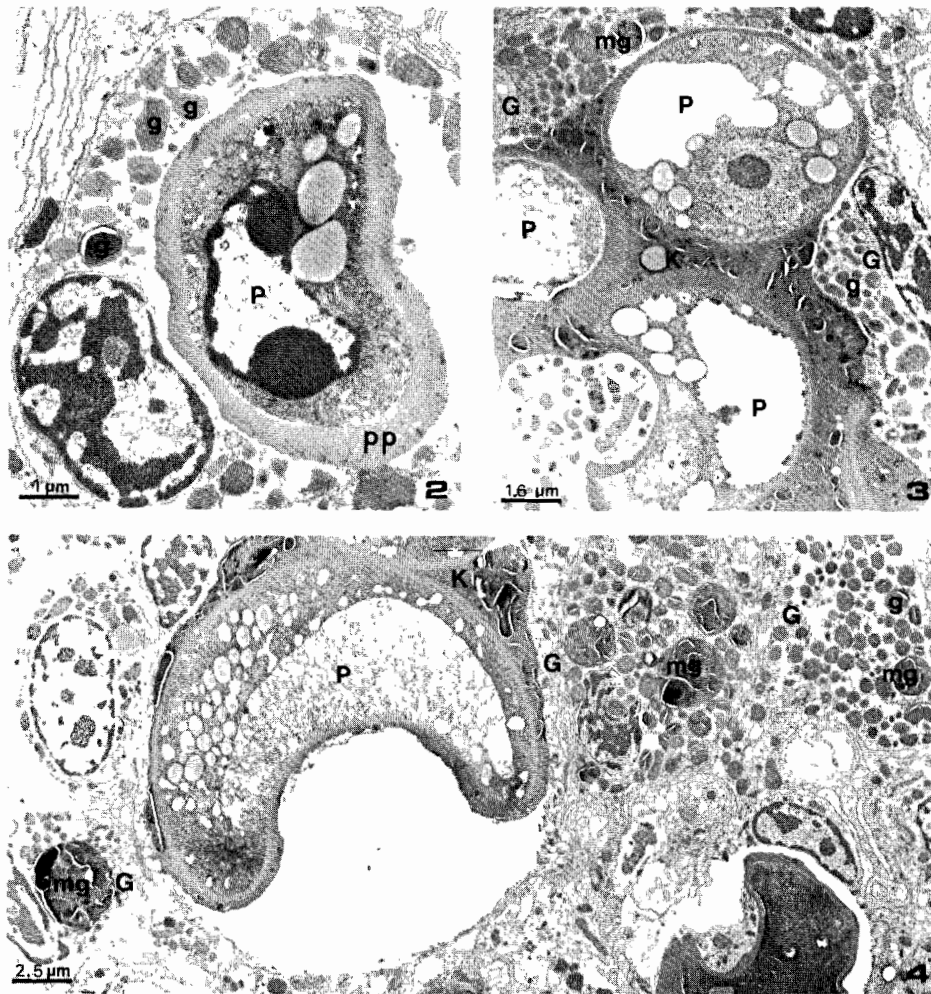
An infection caused by a *Perkinsus*-like parasite has been observed in *Ruditapes decussatus* from Portugal (Comps and Chagot, 1987).

Following a pathological study carried out on clams affected by mortalities in the Algarve area, this parasite was found again, inducing a reaction process in the host.

Histological examination reveals the parasite in the connective tissue of different organs. The adjoining tissues, particularly the epithelia, are not affected. The host reaction consists of inflammatory response producing granulocytoma-like lesions (GR) (Fig. 1). In these granulocytomas, the parasites (P) are isolated, free or phagocytosed, but frequently encysted by a PAS-positive substance; the associated haemocytes are granulocytes which themselves contain PAS-positive granules (g) (Fig. 2). Examinations in the electron microscope show the presence of a thick, pseudoparietal layer of dense material (pp) around the parasites included in the haemocytes (Fig. 2). In several cases, the granulocytes (G) exhibit granules coalescing in macrogranules (mg) (Figs. 3, 4) which seem to produce, by aggregation, cyst-like structures (K) where the parasites appear degenerated.

The characteristics of the reaction induced by this infection of *R. decussatus* are uncommon in comparison with the similar protozoosis known in marine bivalves (Mackin, 1951).





Figs. 1-4. For explanation see text.

REFERENCES

- Comps, M. and Chagot, D., 1987. Une parasitose nouvelle chez la Palourde *Ruditapes decussatus* L. C.R. Acad. Sci. Paris, 304, série III, no. 1: 41-44.
- Mackin, J.G., 1951. Histopathology of infection of *Crassostrea virginica* (Gmelin) by *Dermocystidium marinum* Mackin, Owen and Collier. Bull. Mar. Sci. Gulf Caribb., 1: 72-87.