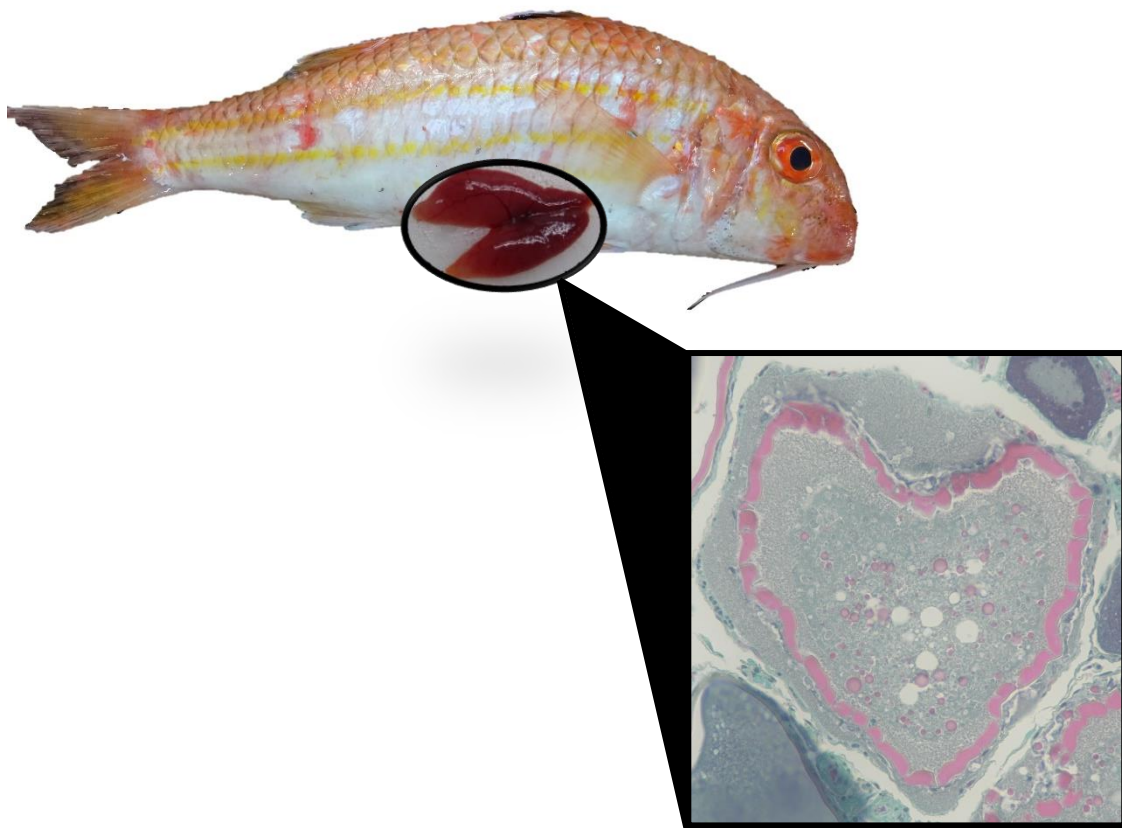


Lexicon of histological structures found in the ovaries and during the oogenesis of the striped red mullet, *Mullus surmuletus* (Linnaeus, 1758)



BERTHELIN Clothilde
DUBROCA Laurent
KELLNER Kristell
LE MELEDER Anna
MARTIN Valentine
SAUGER Carine

April 2023

Cover photo: Picture of a vitellogenic oocyte in atresia found in a red mullet (*Mullus surmuletus*) ovary. Personal collection. C. Sauger©

Lexicon of histological structures found in the ovaries and during the oogenesis of the red mullet, *Mullus surmuletus* (Linnaeus, 1758)

The digital version of this document is available on the Archimer Web site.

The digital version of the reading protocol that accompanies this document is available on the Archimer Web site.

Version	Date	Comments
1.0	April 2022	Conception of the document
2.0	May 2022	Added a cellular structure, sizes and corrections
2.1	August 2022	Figure changes and pictures added
2.2	March 2023	Picture for $oa\beta$ updated
2.3	April 2023	Minor corrections

Summary

Abbreviations.....	1
Introduction.....	2
Overall ovarian organization.....	5
Decision Tree.....	7
Follicle Summary Sheet.....	8
Oogonium (og).....	9
Primary oocyte stage 1 (po1).....	10
Primary oocyte stage 2 (po2).....	11
Lipid droplets oocyte (ldo).....	12
Cortical alveoli oocyte (cao).....	13
Oocyte in early vitellogenesis (vtg1).....	15
Oocyte in vitellogenesis stage 2 (vtg2).....	17
Oocyte in hydration (oih).....	18
Hydrated oocyte (ho).....	20
Post-Ovulatory Follicle (POF).....	21
Atresia (aoA & aoB) and Lysis (L).....	22
Connective tissue (ct) & Gonadal wall (gw).....	25
Blood vessel (bv).....	26
Bibliography.....	27

Abbreviations

aoA : undischarged atretic oocyte
aoB : discharged atretic oocyte
bv : blood vessel
CA : cortical alveoli
cao : cortical alveoli oocyte
chr : condensed chromosome
chrom : chromatin
ct : connective tissue
E : unnatural emptiness (from the section's cut)
fc : follicular cell
gw : gonadal wall
ho : hydrated oocyte
Is : Intercellular space
L : lysis
ld : lipid droplet
ldo : lipid droplets oocyte
mc : macrophage cell
N : nucleus
NC : Nucleo-Cytoplasmic
nl : nucleolus
og : oogonium
oih : oocyte in hydration
po1 : primary oocyte stage 1
po2 : primary oocyte stage 2
POF : Post-Ovulatory Follicle
SI : sexually immature
SM : sexually mature
som : somatic cell
T : theca
U : undetermined structure
vd : vitellus droplet
vi : vitellus
vtg1 : oocyte in stage 1 of vitellogenesis
vtg2 : oocyte in stage 2 of vitellogenesis
zp : zona pellucida



Introduction

During this study, the terminology used was that of Brown-Peterson *et al.* (2011), following the criteria set by the working groups of the International Council for the Exploration of the Sea (ICES) that described the different maturity phases for European stock species (ICES 2008, 2010, 2012, 2018, 2019).

For the description of the female germinal cells that will become gametes, the terms **oogonia** (before meiosis) or **oocyte** (meiosis has begun) will be used. An oocyte is characterized by an **ooplasm** encased in an **oolemma** (plasmic membrane) (Tyler and Sumpter, 1996). A **zona pellucida** will also be present once the cell becomes dependent on follicle-stimulating hormone (FSH).

The term **follicle** will be used to designate an oocyte encased in somatic cells: **follicular cells** and **theca cells** (Tyler and Sumpter, 1996).

For the description of geminal cells development, the term **stage** will be used to designate the different gametogenesis stages (Brown-Peterson *et al.*, 2011) :

- Oogonia
- Primary growth oocytes
- Secondary growth oocytes
- Oocyte maturation
- Ovulation stage

The sexual maturity cycle (*Figure 1*) is split into two **states**. The Sexually Immature (**SI**) state and the Sexually Mature (**SM**) state. The terminology **phase** will be used for the gonadal development. The reproduction cycle of fish is divided into seven **phases** (Brown-Peterson *et al.*, 2011; ICES, 2012; 2018).

- Immature
- Developing
- Spawning
- Regressing
- Regenerating
- Omitted spawning
- Abnormal

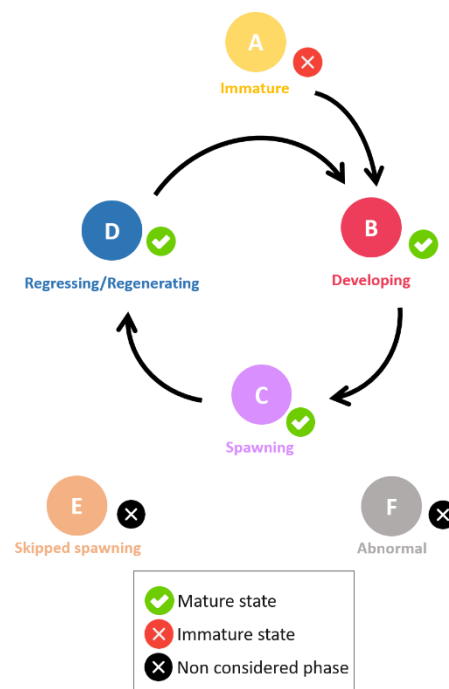


Figure 1 : Different phases found in the teleost maturation cycle, from the ICES (2018). The phases being: Immature (A), Developing (B), Spawning (C), Regressing/Regenerating (D), Skipped spawning (E) and Abnormal (F)

Sub-divisions/Sub-phases (Ba, Bb, Ca, Cb, Da, Db) should be used for specific particularities, meaning that their use is optional and must be evaluated for each species (ICES, 2012).

Table 1 : Macroscopic and microscopic descriptions of the phases in the reproductive cycle of female fish, from Brown-Peterson *et al.* (2011). Timing within each phase is species dependent. Some criteria listed for phases may vary depending on species, reproductive strategy, or water temperature. Subphases that apply to all fishes are listed; additional subphases can be defined by individual researchers. With CA = cortical alveoli, GVBD = germinal vesicle breakdown, GVM = germinal vesicle migration, OM = oocyte maturation, PG = primary growth, POF = post-ovulatory follicle complex, Vtg1 = primary vitellogenic, Vtg2 = secondary vitellogenic and Vtg3 = tertiary vitellogenic

Phase	Previous terminology	Macroscopic and histological features
Immature (never spawned)	Immature, virgin	Small ovaries, often clear, blood vessels indistinct. Only oogonia and PG oocytes present. No atresia or muscle bundles. Thin ovarian wall and little space between oocytes.
Developing (ovaries beginning to develop, but not ready to spawn)	Maturing, early developing, early maturation, mid-maturation, ripening, previtellogenic	Enlarging ovaries, blood vessels becoming more distinct. PG, CA, Vtg1, and Vtg2 oocytes present. No evidence of POFs or Vtg3 oocytes. Some atresia can be present. <i>Early developing subphase</i> : PG and CA oocytes only.
Spawning capable (fish are developmentally and physiologically able to spawn in this cycle)	Mature, late developing, late maturation, late ripening, total maturation, gravid, vitellogenic, ripe, partially spent, fully developed, prespawning, running ripe, final OM, spawning, gravid, ovulated	Large ovaries, blood vessels prominent. Individual oocytes visible macroscopically. Vtg3 oocytes present or POFs present in batch spawners. Atresia of vitellogenic and/or hydrated oocytes may be present. Early stages of OM can be present. <i>Actively spawning subphase</i> : oocytes undergoing late GVM, GVBD, hydration, or ovulation.
Regressing (cessation of spawning)	Spent, regression, postspawning, recovering	Flaccid ovaries, blood vessels prominent. Atresia (any stage) and POFs present. Some CA and/or vitellogenic (Vtg1, Vtg2) oocytes present.
Regenerating (sexually mature, reproductively inactive)	Resting, regressed, recovering, inactive	Small ovaries, blood vessels reduced but present. Only oogonia and PG oocytes present. Muscle bundles, enlarged blood vessels, thick ovarian wall and/or gamma/delta atresia or old, degenerating POFs may be present.

For the histological slides, fresh ovaries were placed in a Davidson solution before their inclusion in paraffin. 3 µm thick sections were cut using a microtome (HM330) and were either trichrome stained with a Prenant-Gabe (Gabe, 1968) solution or Alcian blue stained.

The histological pictures found in this lexicon were taken with a Nikon Eclipse 80i microscope using the NIS-Elements D (v. 5.02.03) software. Mean cell diameters and mean zona pellucida widths were taken with an Olympus AX70 microscope using the Olympus CellSens© software, on a minimum of 20 oocytes found throughout multiple slides.

As seen in Table 1, different **phases** are correlated with the presence or absence of specific cell types. Following the terminologies and definitions of Brown-Peterson *et al.* (2011) and the ICES (2012; 2018). For the red striped mullet (*Mullus surmuletus*), the different cell types described in this work will be shown in bold (**og**, **po1**, **po2**, **ldo**, **cao**, **vtg1**, **vtg2**, **oih**, **ho**, **POF**) while their matching *Figures* will be indicated in italic.

- Oogonium stage :
 - oogonium (**og**) (*Figure 6 & 7*)
- Primary growth oocytes :
 - Primary stage 1 oocyte (**po1**) (*Figures 8 & 9*)
 - Primary stage 2 oocyte (**po2**) (*Figures 10 & 11*)
 - Lipid droplets oocytes (**ldo**) (*Figure 12*)
- Secondary growth oocytes :
 - cortical alveoli oocytes with lipid droplets (**cao**) (*Figures 13 to 15*)
 - vitellogenic oocytes
 - subphase vtg1 : **vtg1** (*Figures 16 to 18*)
 - subphase vtg2 : **vtg2** (*Figure 19*)
- Oocyte maturation :
 - nucleus migration :
 - germinal vesicle breakdown : oocyte enters metaphase I of meiosis
 - vitellus coalescence : oocyte in hydration (**oih**) (*Figures 20 & 21*)
 - hydration : hydrated oocytes (**ho**) (*Figure 22*)
- Ovulation stage : discharge of the hydrated oocytes into the ovary's lumen, leaving behind a post-ovulatory follicle (**POF**) (*Figure 23*)

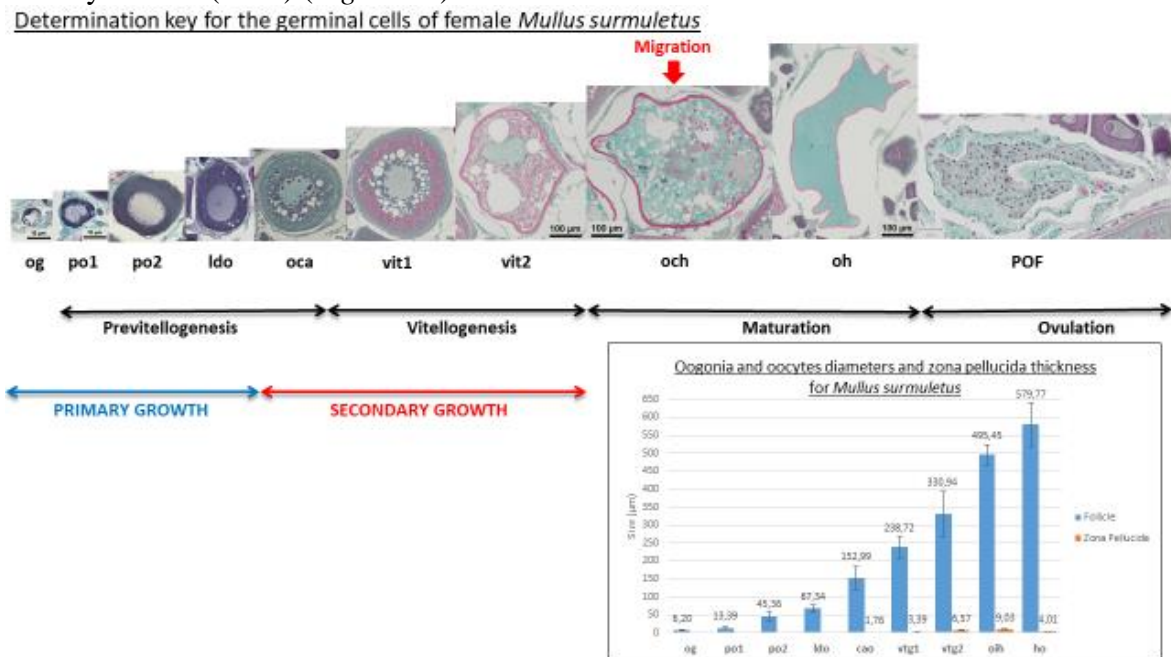


Figure 2 : Determination key for the different female germinal cells that are found in the ovaries of *Mullus surmuletus* at different oogenesis stages. With average oogonium and oocyte diameters ($\mu\text{m} \pm$ standard deviation), and zona pellucida widths ($\mu\text{m} \pm$ standard deviation)

Overall ovarian organization

The red mullet is a **batch spawner** species, meaning that females will release hydrated oocytes multiple times, at different time intervals, during a single breeding season.

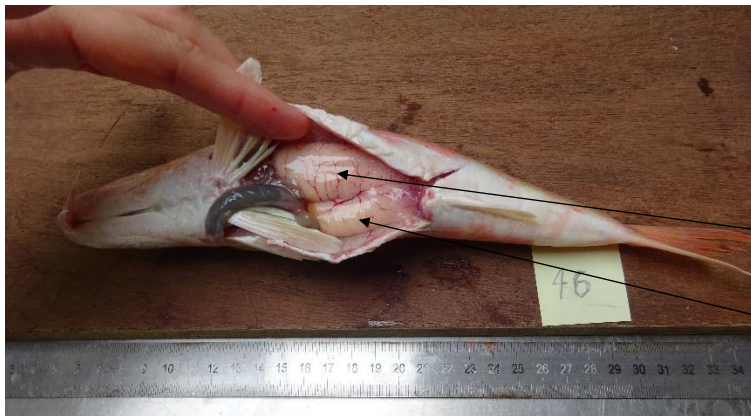

Figure 3 : Dissected female red striped mullet, *Mullus surmuletus*, with both ovaries uncovered

left ovary

right ovary

Criteria like gonadal wall (**gw**) thickness, connective tissue (**ct**) quantity, gonad vascularization (**bv**) or the surface area of the **lumen**, will depend on the fish's maturity phase. The histological cross sections will be visually different, with germinal cells at various stages of oogenesis.

Each gonad is organized concentrically (*Figure 4* and *Figure 5*), with the ovarian lamellas delimited by the germinal epithelium. The germinal cells (oogonia and oocytes) are found within these ovarian lamellas, inside follicles, at different stages of oogenesis. The connective tissue (**ct**) will hold the germinal cells together, and the gonad wall (**gw**) can vary in thickness. Finally, the **lumen** is the naturally empty space found between the germinal epithelium lamellas inside the ovary.

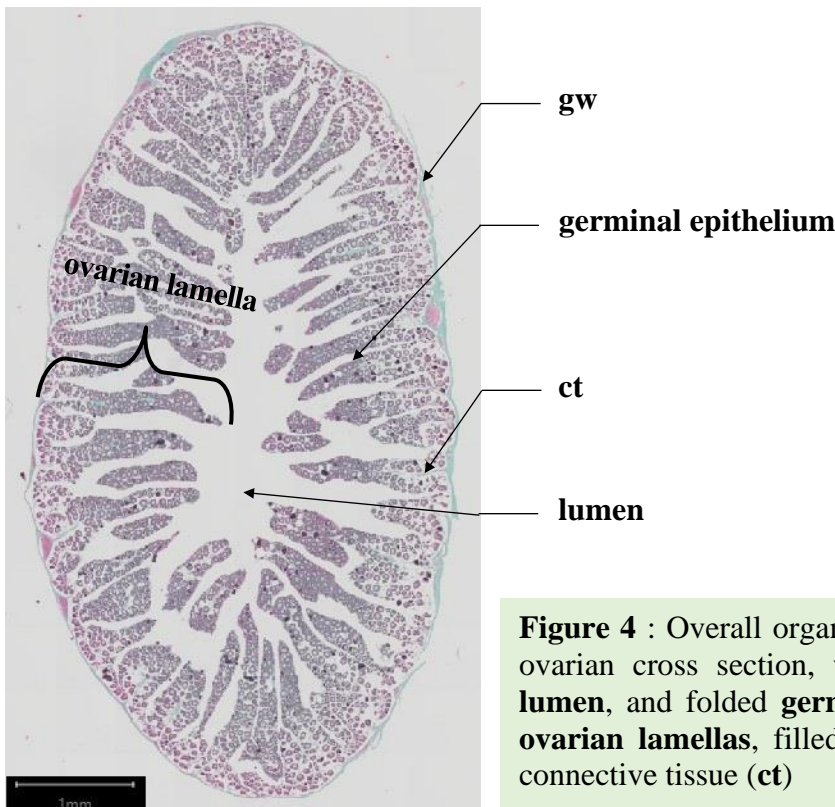


Figure 4 : Overall organization of a red striped mullet's ovarian cross section, with the gonad wall (**gw**), the **lumen**, and folded **germinal epithelium** that make the **ovarian lamellas**, filled with oocytes held together by connective tissue (**ct**)

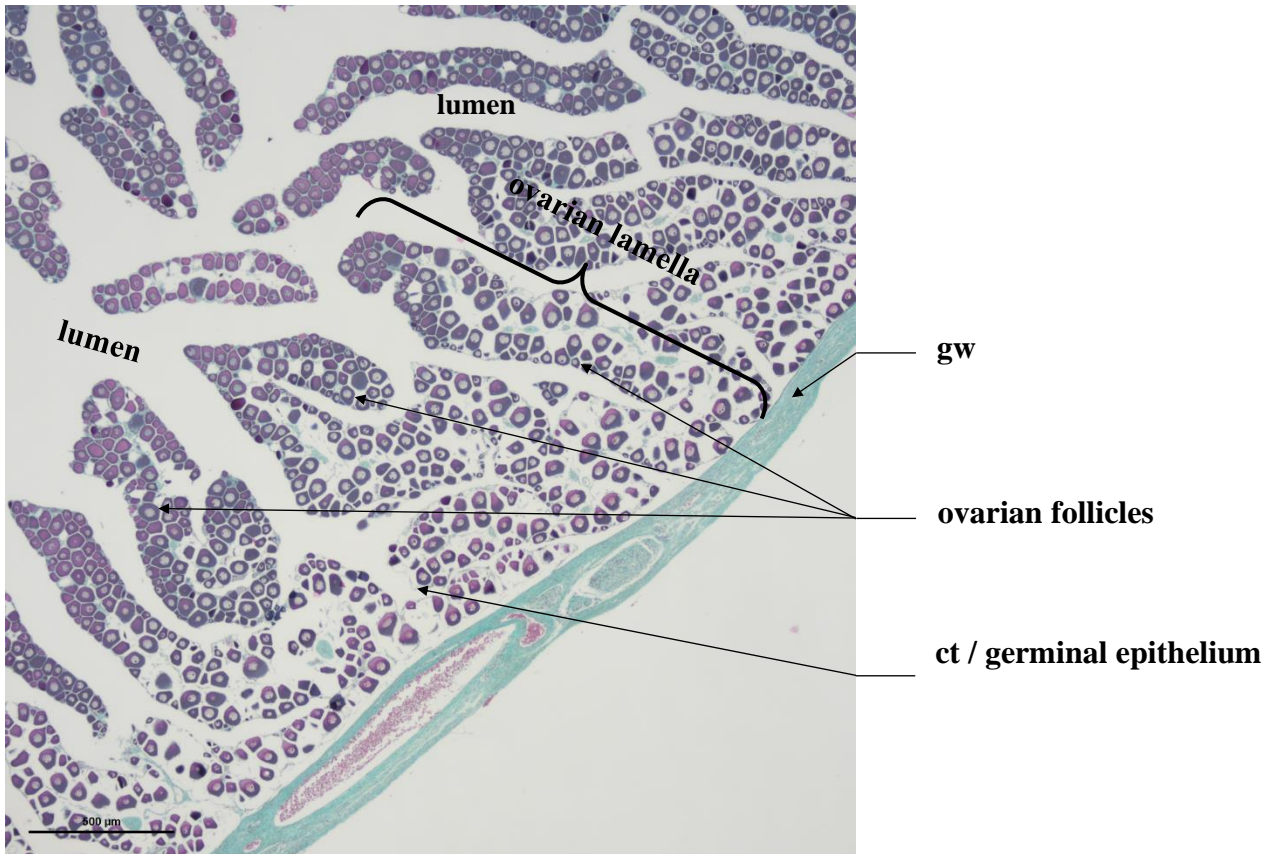
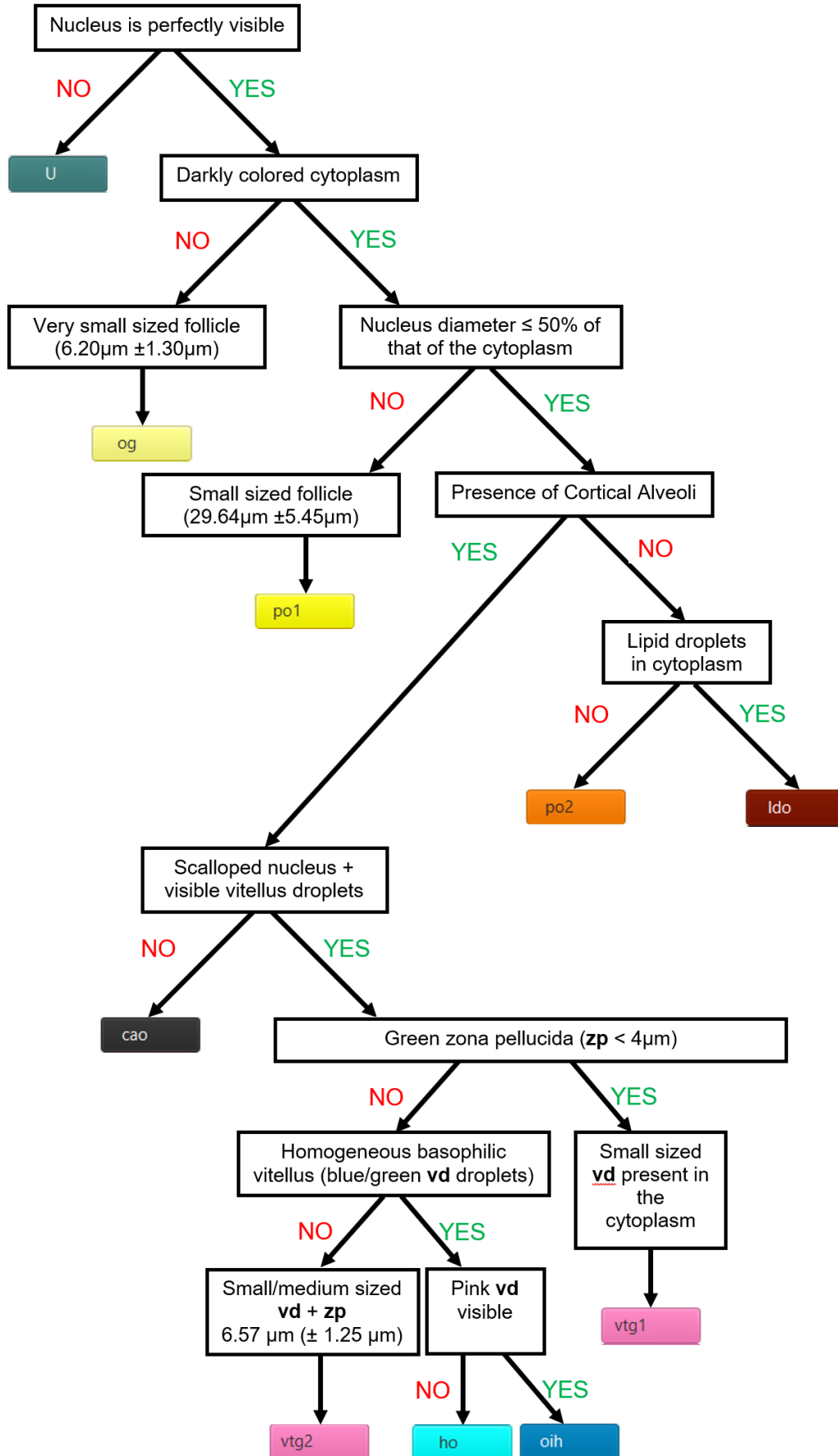


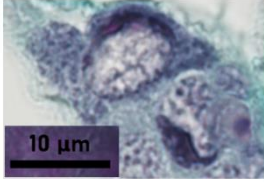
Figure 5 : Partial view of a red striped mullet ovary cross section, with the gonad wall (**gw**), the **lumen**, and oocytes in **follicles** held together by connective tissue (**ct**), organized inside **ovarian lamellas**

Decision Tree



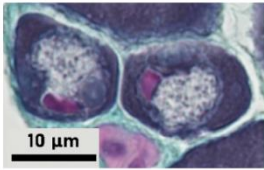
Follicle Summary Sheet

og



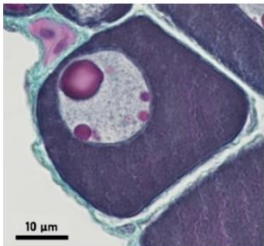
6.20µm (±1.30µm)
Light gray nucleus taking most of the space, barely visible light-colored cytoplasm with chromatin. Single nucleolus may be present

po1



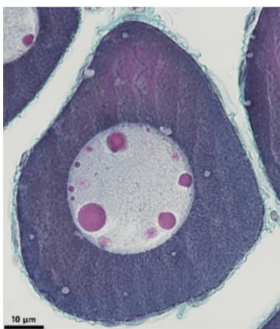
13.39µm (±3.40µm)
Nucleus diameter >50% of the cytoplasm's. Nucleus is visible, smooth and round, one or two nucleoli can be present. Dark colored cytoplasm

po2



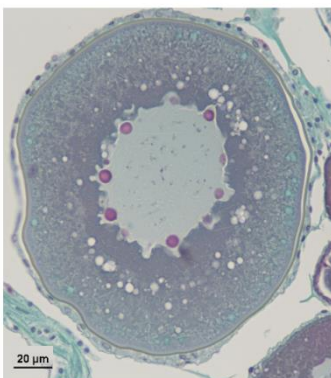
45.36µm (±10.48µm)
Nucleus is visible, smooth and round. Many nucleoli can be present. Dark colored cytoplasm

ldo



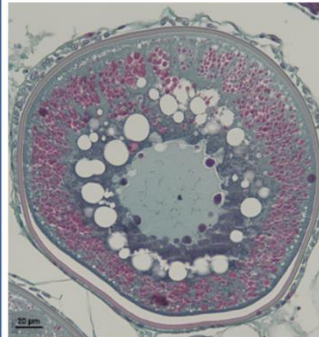
67.34µm (±11.28µm)
Nucleus is visible, smooth or slightly scalloped, many nucleoli. Dark colored cytoplasm containing white lipid droplets

cao



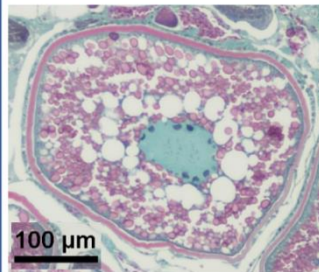
152.99µm (±31.65µm)
Cortical alveoli near the outer periphery, green zona pellucida (1.76µm±0.42µm), scalloped nucleus with multiple nucleoli, growing white lipid droplets in the cytoplasm

vtg1



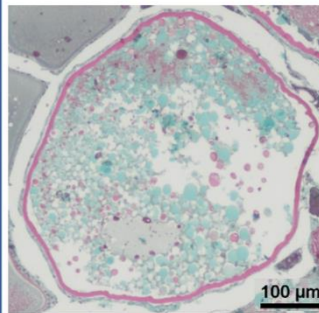
238.72µm (±30.55µm)
First appearance of small pink vitellus droplets amongst the cortical alveoli, under the thin greenish zona pellucida (3.39µm±0.85µm). Scalloped nucleus with multiple nucleoli. Large lipid droplets around the nucleus

vtg2



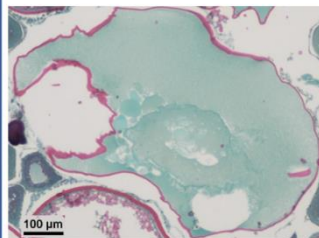
330.94µm (±61.21µm)
Zona pellucida thickens (6.57µm±1.25µm) and is pink and striated. Large vitellus droplets take up the entire space in the cytoplasm. Lipid droplets fuse and become bigger

oih



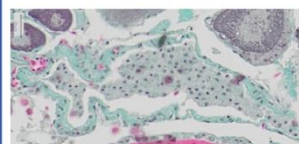
495.45µm (±29.01µm)
Vitellus droplets fuse and take a turquoise color. The zona pellucida (9.03µm±1.06µm) is pink and striated

ho



579.77µm (±61.12µm)
Homogeneous basophilic vitellus (turquoise blue areas). Zona pellucida (4.01µm±0.63µm) pink and striated.

POF



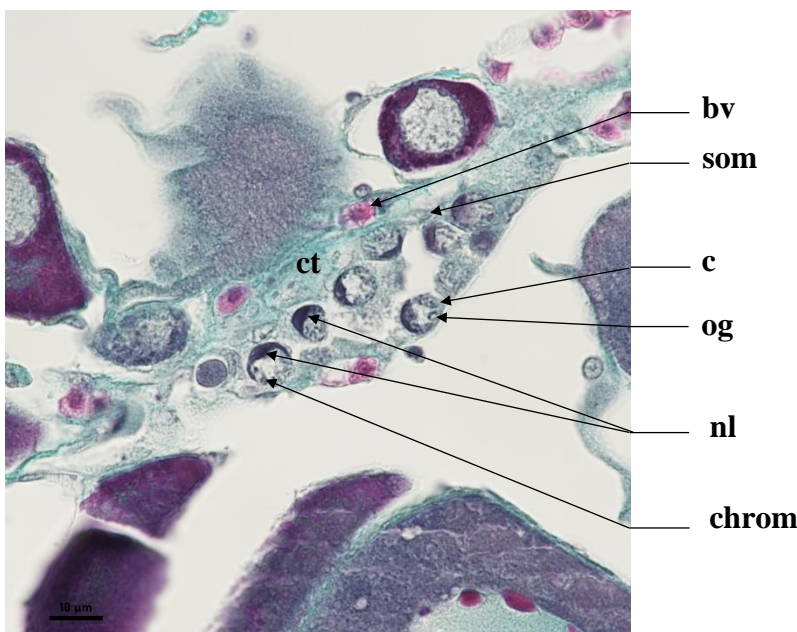
Empty theca, green colored like connective tissue. Macrophage cells may be present. Great variability in size



Oogonium (og)

An oogonium (**og**) has a pale nucleus (**N**), due to low chromosome condensation, and a high nucleo-cytoplasmic (NC) ratio (very little cytoplasm). Chromatin clusters can be seen near the edges of the nucleus. Inside this nucleus, a single large nucleolus can generally be found. The cytoplasm (**c**) is light-colored (*Figure 6*). Oogonia stem from germinal cells through gonial mitosis. They can be found alone or in a germinal niche within the germinal epithelium, accompanied by somatic cells (**som**).

Identification : It is uncommon to fall on this very small sized cell. The **nucleus is light-gray and fully apparent** while the **cytoplasm is barely visible and very light-colored**. A **single light-colored and smooth nucleolus** can be present. The diameter of the nucleus of an oogonium is greater than the surface area of the cytoplasm (>50 %).



Average size
og : 6.20 µm (± 1.30µm)

Figure 6 : Germinal niche surrounded in connective tissue (**ct**) with oogonia (**og**) and their apparent, decondensed, nucleus with a single large nucleolus (**nl**) and clusters of chromatin (**chrom**). Light-colored cytoplasm (**c**). Presence of somatic cells (**som**) and blood vessels (**bv**)

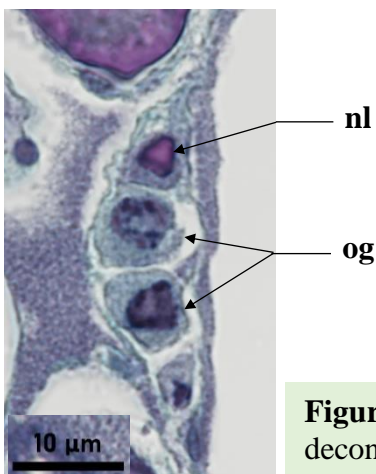


Figure 7 : Oogonias (**og**) and their apparent decondensed nucleus and single nucleolus (**nl**)



Primary oocyte stage 1 (po1)

A primary oocyte stage 1 (**po1**) has a darker cytoplasm (**c**) compared to an oogonium (**og**), with a smaller **NC** ratio. The diameter of the cytoplasm is inferior or equal to 50 % of the nucleus' diameter. The nucleus (**N**) is spherical, smooth, with the possibility of one or two visible nucleoli. It is sometimes possible to see lampbrush chromosomes inside the nucleus, typically found in immature diplotene oocytes.

Identification : This cell type is slightly bigger than an oogonium, but is still relatively small in size compared to the other cellular structures found inside the ovary. Falling on this follicle in stereology is still uncommon. The **nucleus must be fully visible, smooth, and the cytoplasm is darkly-colored**. The nucleus diameter of a **po1** is superior to 50 % of the cytoplasm's diameter, and can contain up to **2 nucleoli**. If there is a hesitation between a **po1** and a **po2**, the cell size can be taken into consideration. Somatic cells (**som**) may be seen nearby.

Average size
po1 : 13.39 μm (\pm 3.40 μm)

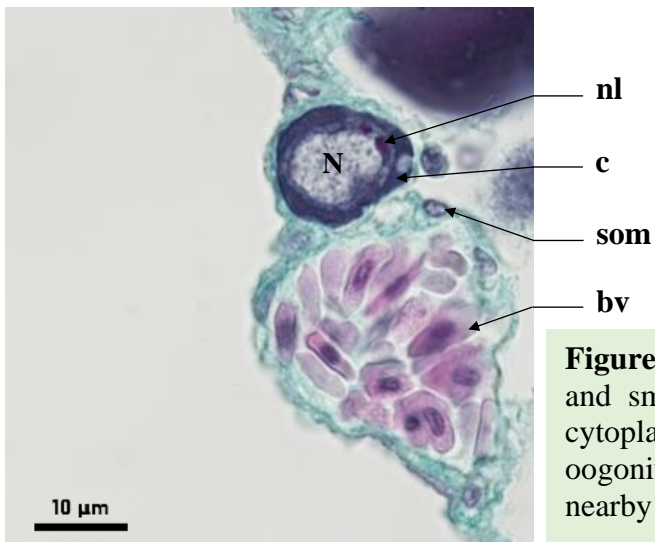


Figure 8 : Primary oocyte stage 1 (**po1**) with a spherical and smooth nucleus (**N**) and two nucleoli (**nl**). The cytoplasm (**c**) is darker compared to that of an oogonium. Somatic cells (**som**) and blood cells (**bv**) are nearby

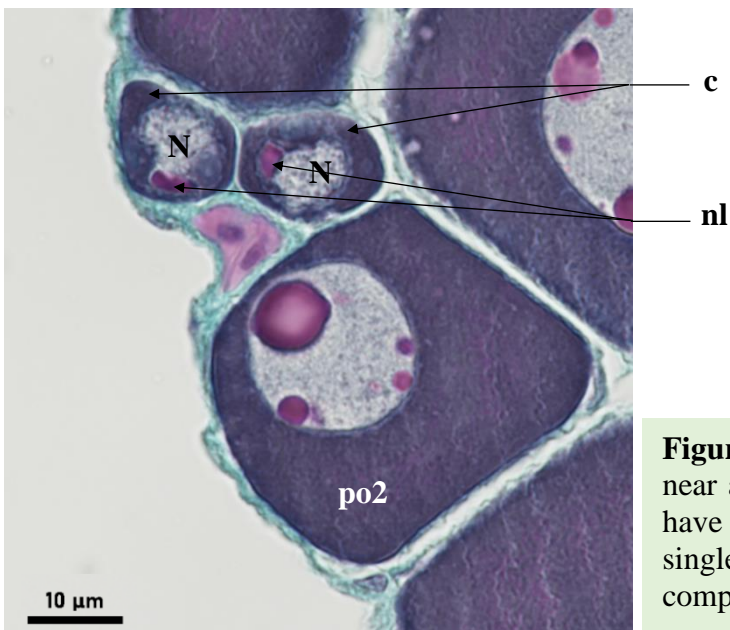


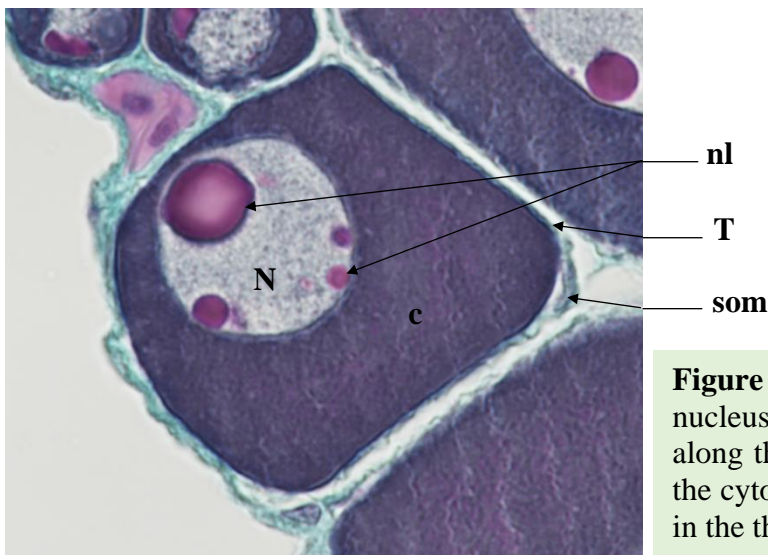
Figure 9 : Two primary oocytes stage 1 (**po1**) near a primary stage oocyte stage 2 (**po2**). **po1** have a spherical and smooth nucleus (**N**) with a single nucleolus (**nl**). The cytoplasm (**c**) is darker compared to that of an oogonium (**og**)



Primary oocyte stage 2 (po2)

A primary oocyte stage 2 (**po2**) has a dark colored cytoplasm (**c**), with a high **NC** ratio. The diameter of the cytoplasm is superior or equal to 50 % of the nucleus' diameter. The nucleus (**N**) is spherical, smooth, with the possibility of multiple nucleoli. They vary in sizes and are present along the nuclear envelope. It is sometimes possible to see lampbrush chromosomes inside the nucleus, typically found in immature diplotene oocytes.

Identification : This ovarian follicle varies in size, between the **po1** and **cao** stage. The **nucleus must be fully visible, smooth, and the cytoplasm is darkly-colored**. The nucleus diameter of a **po2** is inferior or equal to 50 % of the cytoplasm's diameter, and can contain **multiple nucleoli of different sizes** against the nuclear envelope. If there is a hesitation between a **po1** and a **po2**, the cell size can be taken into consideration.



Average size
po2 : 45.36 μm (\pm 10.48 μm)

Figure 10 : A **po2** with a spherical and smooth nucleus (**N**) filled with multiple nucleoli (**nl**) along the inside of its nuclear envelope, inside the cytoplasm (**c**). A somatic cell (**som**) is seen in the theca (**T**)

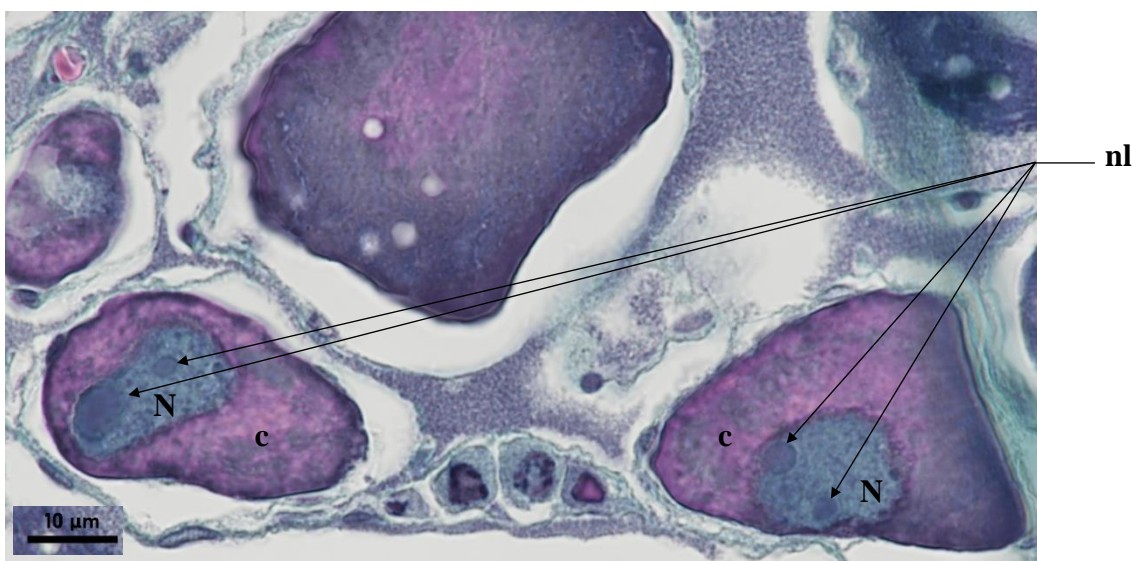


Figure 11 : Two **po2**, with spherical and smooth nucleus (**N**) filled with multiple nucleoli (**nl**). The cytoplasm (**c**) is large and homogenous

Lipid droplets oocyte (ldo)

Before reaching the cortical alveoli (cao) stage, the follicle will grow in size and accumulate lipid droplets (ld) in its cytoplasm (c). These lipid droplets first appear along the outer periphery of the cytoplasm. They will later gather around the nucleus (N). The nucleus is smooth, round and contains multiple nucleoli (nl) against its nuclear membrane. Staining follicles Alcian blue shows that the vesicles in the cytoplasm are unstained : they do not contain acidic polysaccharides and probably consist in lipid droplets. Lampbrush chromosomes may sometimes be seen in the nucleus.

Identification : A lipid droplet oocyte (ldo) is characterized by a **smooth and round nucleus** with **multiple nucleoli** along its nuclear membrane. **White lipid droplets** are present in the cytoplasm.

Average size

ldo : $67.34\mu\text{m} (\pm 11.28\mu\text{m})$

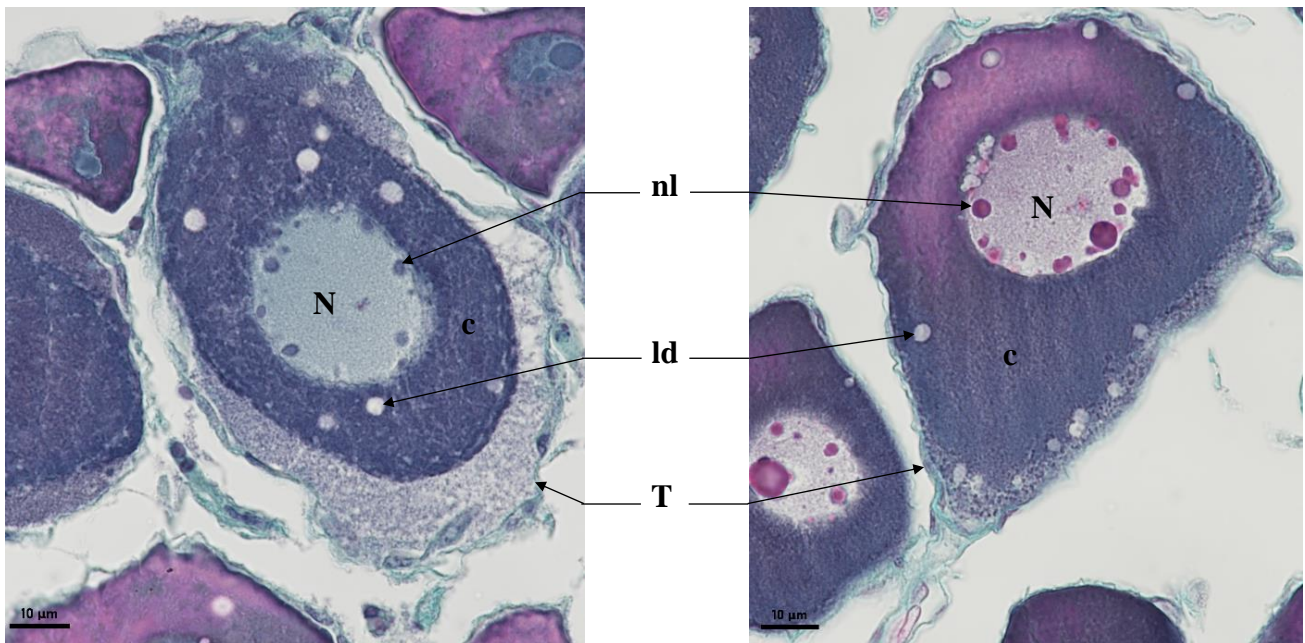


Figure 12 : Lipid droplet oocytes (ldo) with white lipid droplets (ld) in the cytoplasm (c). The nucleus (N) is round and smooth and holds multiple nucleoli (nl) along its nuclear envelope, surrounded by a theca (T)

Cortical alveoli oocyte (cao)

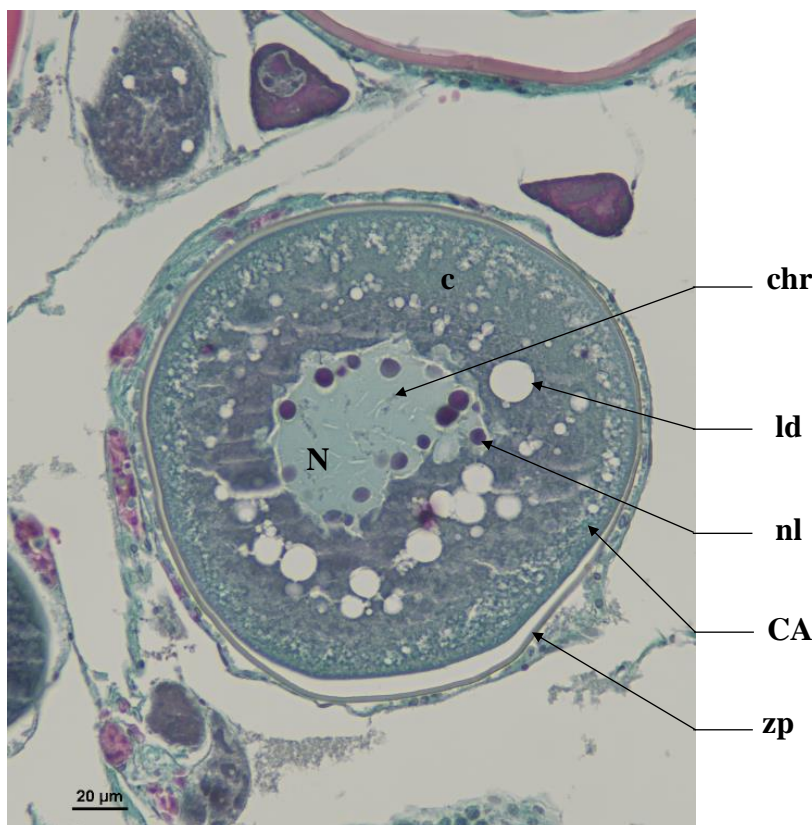
An oocyte with cortical alveoli (**cao**) is defined by the first appearance of cortical alveoli (**CA**) in the cytoplasm (**c**), on the periphery of the oocyte, under the somatic cells layer. The nucleus (**N**) is in the center of the cytoplasmic mass, with a smooth or slightly scalloped nuclear envelope and multiple nucleoli (**nl**) against it. Sometimes, it is possible to see lampbrush chromosomes (**chr**) inside the nucleus, typically found in immature diplotene oocytes.

As the **cao** matures, the **CA** and lipid droplets (**ld**) will grow in size and take more place inside the cytoplasm, with small **CA** against the outer periphery in the cytoplasm. At this point, the nucleus is scalloped and filled with multiple nucleoli against the nuclear envelope.

The oolemma will start to grow and the zona pellucida (**zp**) will start developing between the cytoplasm and the follicular cells (**fc**) + theca (**T**). The zona pellucida (**zp**) is thin and green/yellowish (not acidophilus).

The **CA** will appear in the outer periphery of the outer cytoplasm. Only the Alcian blue coloration, which gives them blue color, allows us to differentiate perfectly them from other structure. With the trichrome stain, it is possible to observe some **CA**, with a turquoise blue coloring.

Identification : An oocyte with cortical alveoli is primarily defined by a the **presence of cortical alveoli in the cytoplasm**, with a first appearance on the outer periphery of the cytoplasm. The **nucleus in the center of the follicle contains multiple nucleoli** along its **scalloped nuclear envelope**.



Average size

cao : 152.99 μm (± 31.65μm)

zp : 1.76 μm (± 0.42μm)

Figure 13 : Cortical alveoli oocyte (**cao**) with a scalloped nucleus (**N**) holding multiple nucleoli (**nl**) and lampbrush chromosomes (**chr**). Cortical alveoli (**CA**) and lipid droplets (**ld**) build-up in the cytoplasm (**c**) and the zona pellucida (**zp**) forms

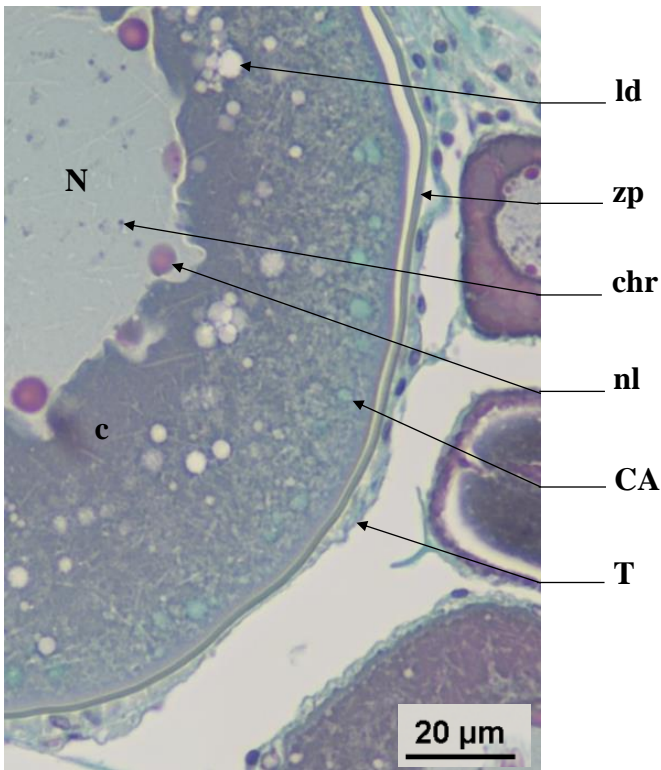


Figure 14 : Cell wall of an oocyte with cortical alveoli (**cao**), with Gabe's trichrome stain to give a turquoise blue color to the cortical alveoli (**CA**). The nucleus (**N**) is scalloped and contains multiple nucleoli (**nl**) along its nuclear envelope. Lampbrush chromosomes can be seen (**chr**). Large lipid droplets (**ld**) start to build-up around the **N**, in the cytoplasm (**c**). Cortical alveoli (**CA**) start to form on the periphery of the cytoplasm, under the green zona pellucida (**zp**) that is beginning to grow under the theca (**T**)

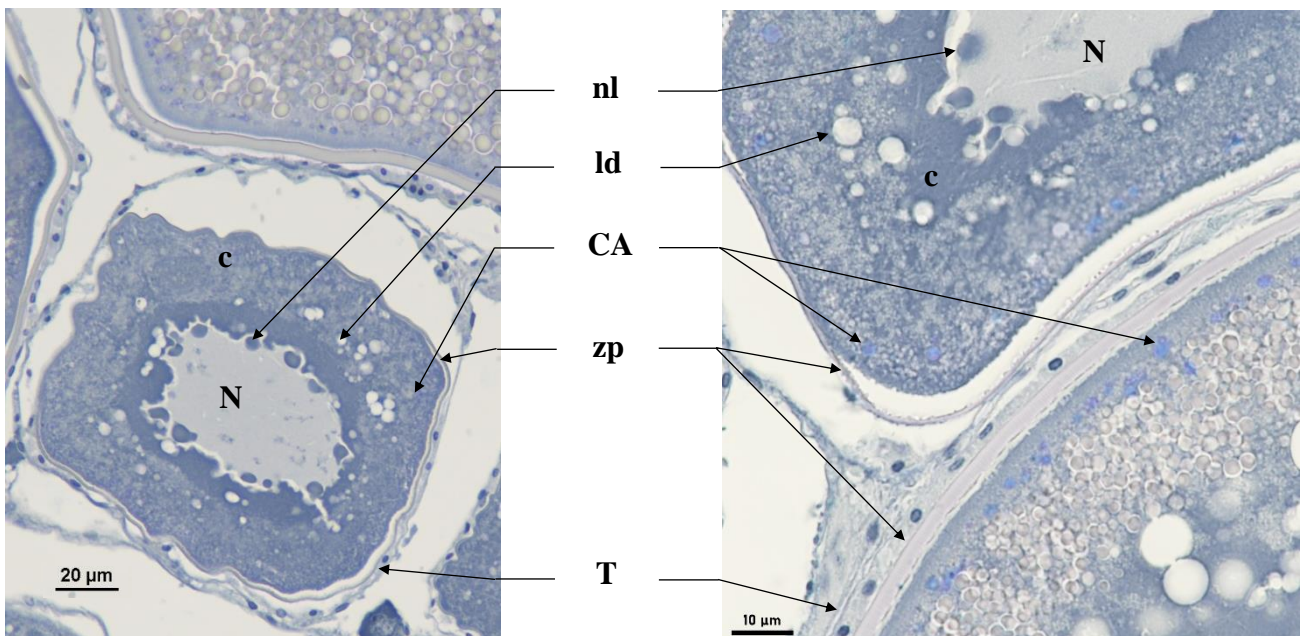


Figure 15 : Cortical alveoli oocytes (**cao**) Alcian blue stained to highlight the cortical alveoli (**CA**) in purple-blue. **cao** have a scalloped nucleus (**N**) holding multiple nucleoli (**nl**). **CA** build-up in the cytoplasm (**c**) near the outer periphery of the follicle while lipid droplets (**ld**) gather around the **N**. The zona pellucida (**zp**) is forming under the theca (**T**)

Oocyte in early vitellogenesis (vtg1)

An oocyte at the beginning of the vitellogenic stage (**vtg1**) is defined by the presence of vitellus droplets (**vd**), pink eosinophilic droplets, that form in the periphery of the cytoplasm (**c**), under the somatic cell layer. The zona pellucida (**zp**) will thicken but keep a green tint. The nucleus (**N**) is still centered in the follicle, with multiple nucleoli (**nl**) along the scalloped nuclear envelope.

As the cell matures, lipid droplets (**ld**) around the **N**, cortical alveoli (**CA**) in the outer periphery of the cytoplasm and vitellus droplets (**vd**) in the cytoplasm between the **ld** and **CA**, will grow in size.

Identification : This oocyte in early vitellogenesis is identifiable by the appearance of **pink vitellus droplets in the outer periphery of the cytoplasm**. At the **first appearance of a vitellus droplet**, the oocyte is considered to be in the **vtg1** stage, **even if the nucleus (N) is not visible**. The **nucleus is still scalloped and centered inside the follicle**, containing multiple the nucleoli. **Vitellus droplets usually run along the edge of the inner cell wall**, along the zona pellucida (**zp**) and amongst the cortical alveoli (**CA**). **The zona pellucida (zp) is small and green**, as it thickens under the Theca (**T**).

Average size

vtg1 : 238.72 μm (\pm 30.55 μm)

zp : 3.39 μm (\pm 0.85 μm)

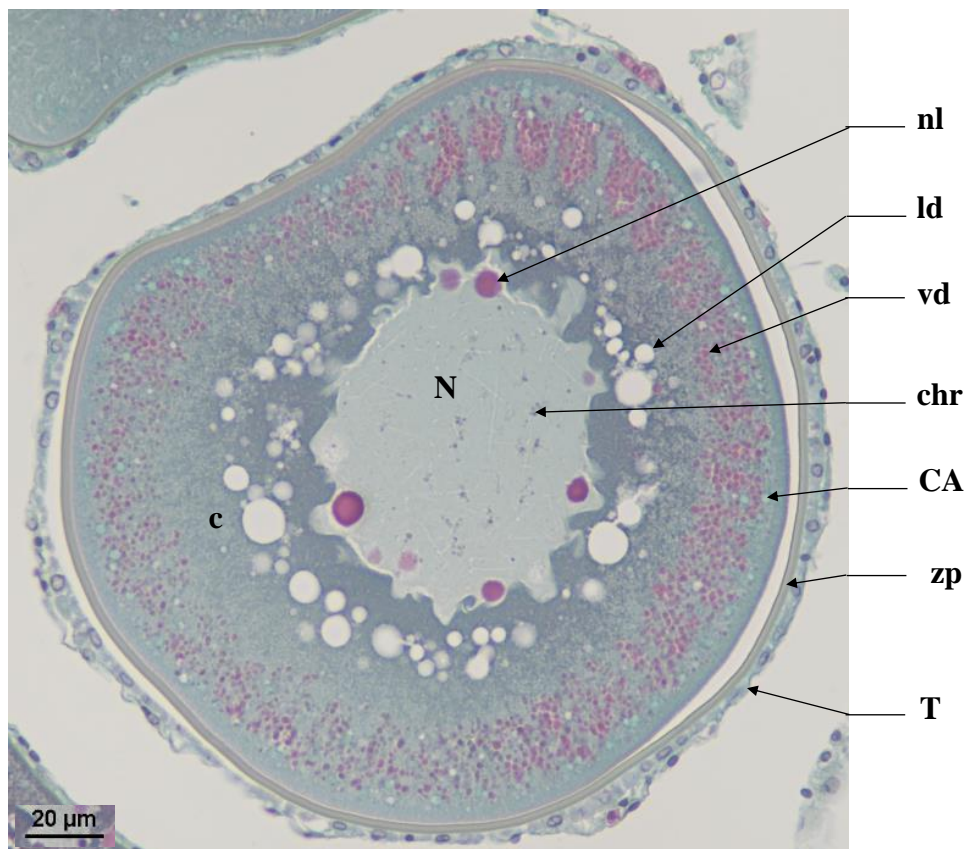


Figure 16 : An early stage **vtg1** oocyte, with a scalloped nucleus (**N**) containing multiple nucleoli (**nl**) and lampbrush chromosomes (**chr**). Vitellus droplets (**vd**) form on the outer periphery of the cytoplasm (**c**) amongst the cortical alveoli (**CA**) under the green zona pellucida (**zp**) under a layer of somatic cells forming the theca (**T**). Large lipid droplets (**ld**) aggregate around the **N**

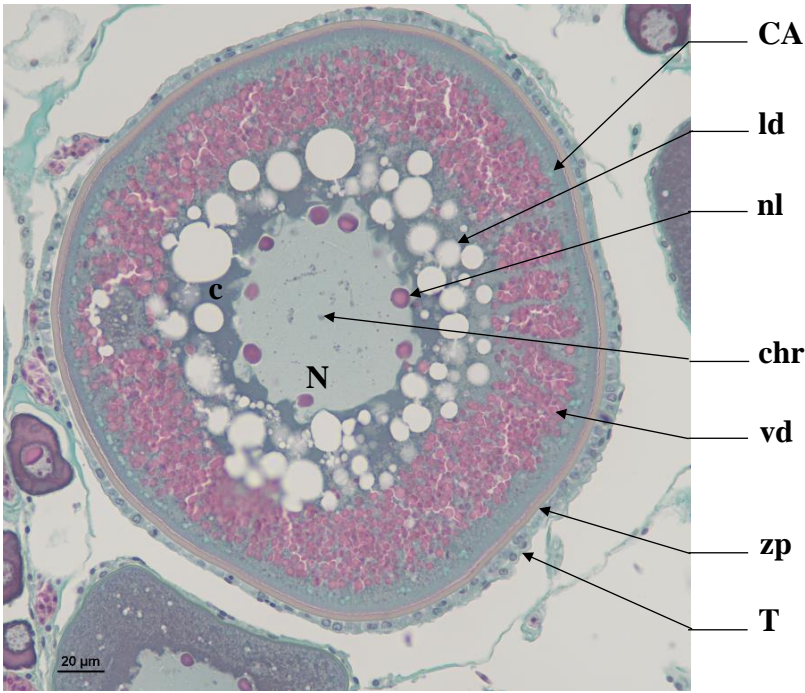


Figure 17 : A late stage **vtg1** oocyte, with a scalloped nucleus (**N**) envelope containing multiple nucleoli (**nl**) and lampbrush chromosomes (**chr**). Vitellus droplets (**vd**) fill the cytoplasm (**c**) from the outer periphery, amongst the cortical alveoli (**CA**) under the zona pellucida (**zp**) that is starting to take a pink tint under theca (**T**). Large lipid droplets (**ld**) aggregate around the **N**

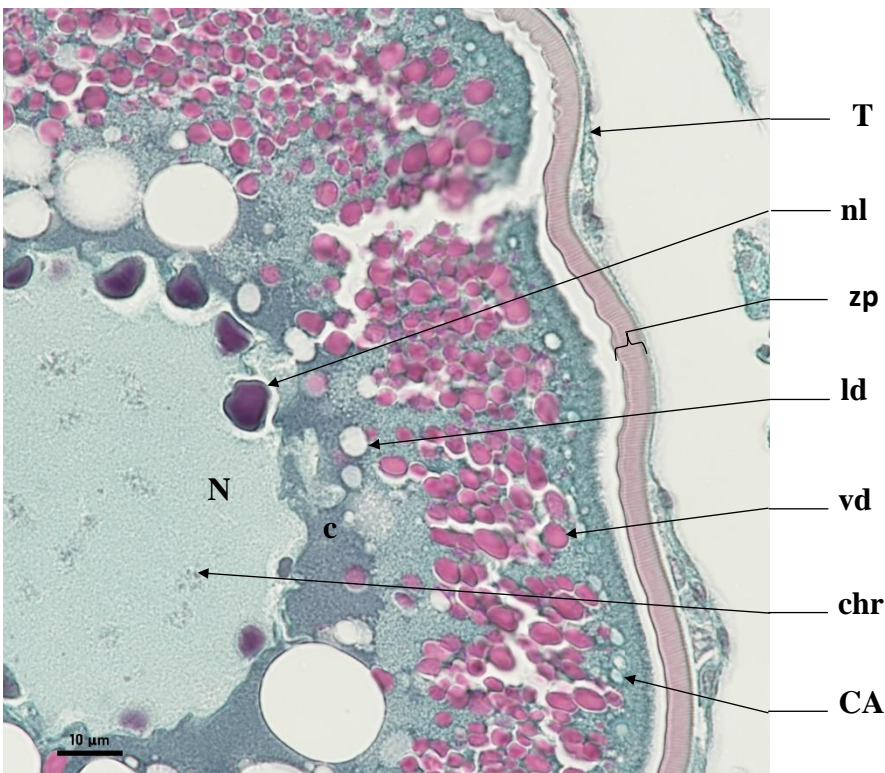


Figure 18 : Cell wall of a **vtg1** oocyte with a scalloped nucleus (**N**) containing multiple nucleoli (**nl**) and lampbrush chromosomes (**chr**). Vitellus droplets (**vd**) form on the outer periphery of the cytoplasm (**c**), amongst the cortical alveoli (**CA**) under the zona pellucida (**zp**) that is starting to take a pink tint under theca (**T**). Large lipid droplets (**ld**) aggregate around the **N**



Oocyte in vitellogenesis stage 2 (vtg2)

During the **vtg2** stage, the zona pellucida (**zp**) thickens and becomes striated as it takes on a pink tinge. The vitellus droplets (**vd**) will take up the entire space inside the follicle as they start to fuse together and grow in size. The lipid droplets (**ld**) fuse together into larger masses. The nucleus (**N**) is still scalloped and contains multiple nucleoli (**nl**).

Identification : A **vtg2** oocyte is defined by a **pink, thick, and slightly striated zp**, as well as **small to medium sized vitellus droplets (vd) that take up the entire space inside the follicle**. Lipid droplets (**ld**) have fused into bigger masses. It is preferable, but not mandatory for the nucleus to be visible.

Average size

vtg2 : 330.94 μm (\pm 61.21 μm)

zp : 6.57 μm (\pm 1.25 μm)

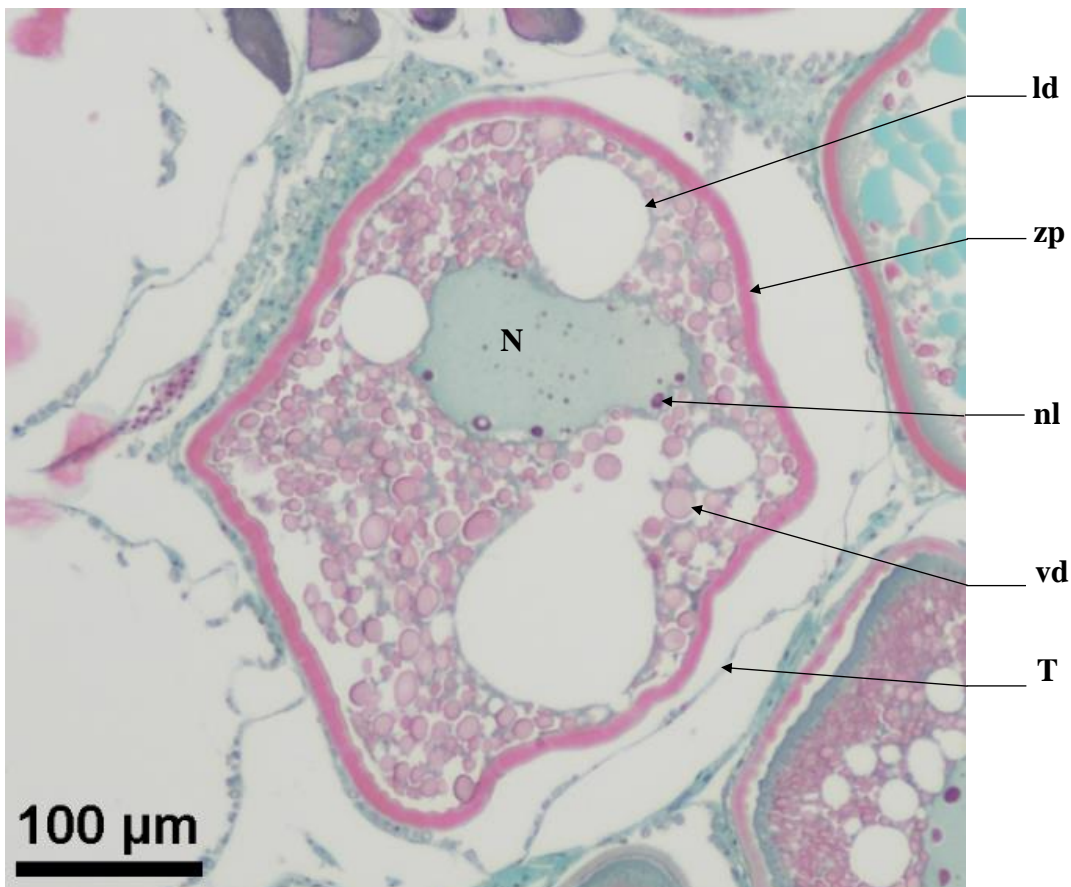


Figure 19 : Stage **vtg2** oocyte, with a scalloped nucleus (**N**) containing multiple nucleoli (**nl**). The zona pellucida (**zp**) is pink and slightly striated. Medium sized vitellus droplets (**vd**) take up the entire space inside the follicle. Large lipid droplets (**ld**) are also present

Oocyte in hydration (oih)

During the oih stage, the nucleus (N) migrates and progressively approaches the oocyte's periphery until it is pushed up against the zona pellucida. The vitellus droplets (vd) become turquoise blue and gradually fuse together, giving way to zones of homogeneous basophilic vitellus (vi) (turquoise blue areas). The zona pellucida (zp) is pink, striated and at its thickest.

Identification : The vd fuse to become turquoise blue and to break down to form a **zone of homogeneous vitellus (turquoise blue areas)**. The zona pellucida will be pink, striated and at its thickest. The nucleus can sometimes be seen, but its visibility is not mandatory for the identification of this stage.

Average size

oih : 495.45 μm (\pm 29.01 μm)

zp : 9.03 μm (\pm 1.06 μm)

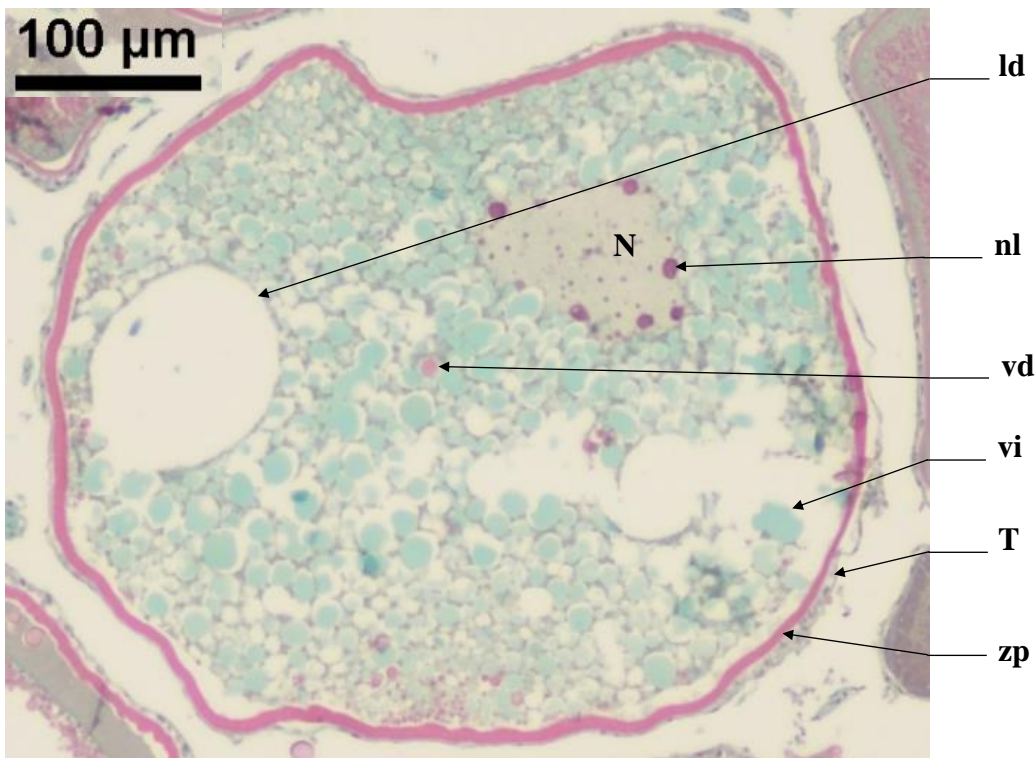


Figure 20 : Oocyte in hydration (oih) with a pink zona pellucida (zp) under the theca (T). The scalloped nucleus (N) has nucleoli (nl). Vitellus droplets (vd) fuse and break down into a homogeneous vitellus (vi), and large lipid droplets (ld) are present

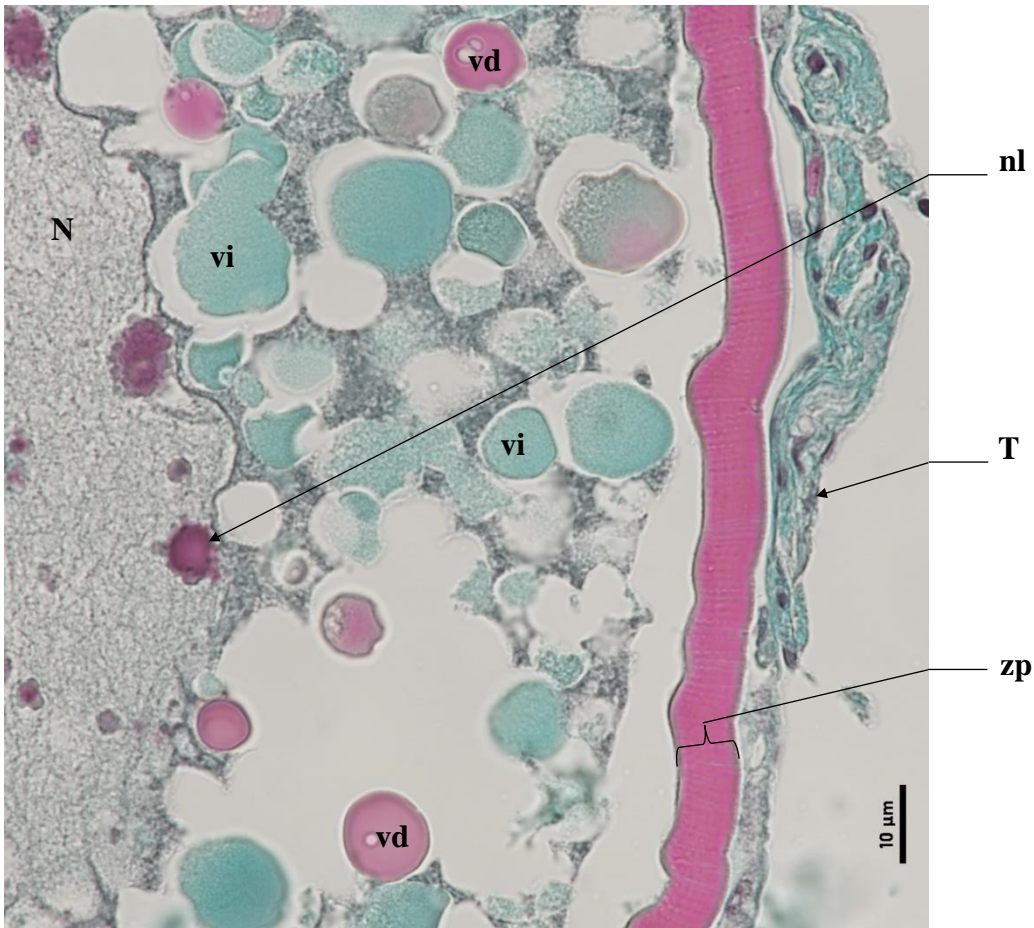


Figure 21 : Cell wall of an oocyte in hydration (**oih**) with a pink, thick and striated zona pellucida (**zp**) under the theca (**T**). The scalloped nucleus (**N**) has nucleoli (**nl**). Vitellus droplets (**vd**) fuse and break down into a homogeneous vitellus (**vi**), and large lipid droplets (**ld**) are present

Hydrated oocyte (ho)

A hydrated oocyte (**oh**) is defined by a turquoise blue homogeneous vitellus (**vi**) that takes up the entire volume of the oocyte. A few lipid droplets (**ld**) can sometimes be seen near the thick and striated zona pellucida (**zp**).

Identification : Biggest cell type found in the ovary. Because of the dehydration process, this type of oocyte doesn't always have a smooth and circular shape, and the theca (**T**) may be detached from the zona pellucida (**zp**). Whether this oocyte has been discharged from its follicle in the lamella or not, this cell type will be categorized as **oh**. The **zp** is pink, thick and striated, and the **oocyte** is filled entirely with homogeneous vitellus (turquoise blue color).

Average size

ho : 579.77 μm (\pm 61.12 μm)

zp : 4.01 μm (\pm 0.63 μm)

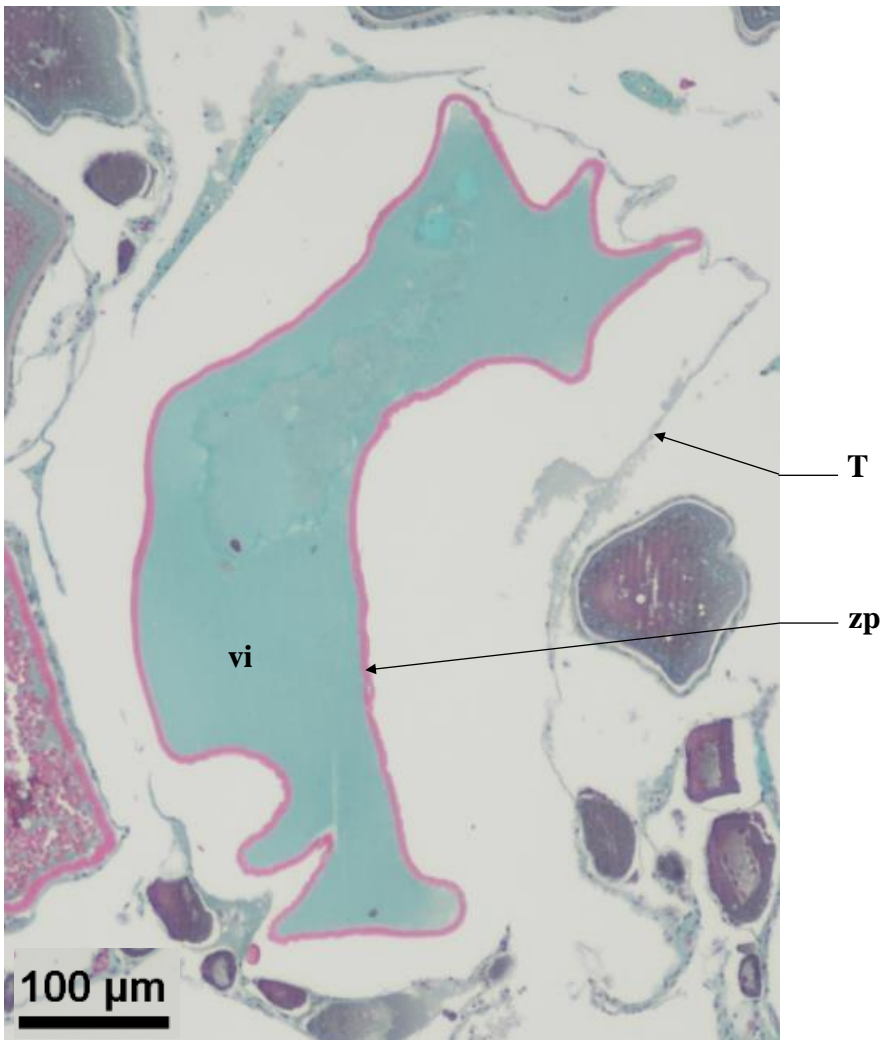


Figure 22 : Hydrated oocyte (**oh**) that has not been discharged still encased within its theca (**T**), with a homogeneous vitellus (**vi**) and a thick, pink and striated zona pellucida (**zp**)

Post-Ovulatory Follicle (POF)

A Post-Ovulatory Follicle (**POF**) may show signs of lysis, with the presence of macrophage cells (**mc**) inside their cavity. A **POF** indicates that a hydrated oocyte (**oh**) has been discharged into the lumen. A **POF** is composed of all the somatic tissues of the follicle (theca (**T**) and follicular cells (**fc**)) left behind after the mature oocyte (**oh**) has been discharged into the lumen. Their green dye is identical to that of connective tissue (**ct**). Be careful not to put a **POF** into the **ct** category. **POF** vary in size and shape and are essentially empty sockets that have receded onto themselves.

Identification : A **POF** is a sack of somatic tissue that may be identified by the presence of macrophage cells inside its cavity. Macrophage cells (**mc**) are very small, gray tinged, and are often found clustered together. A **POF** will vary greatly in size and shape and can easily be mistaken with connective tissue (**ct**).

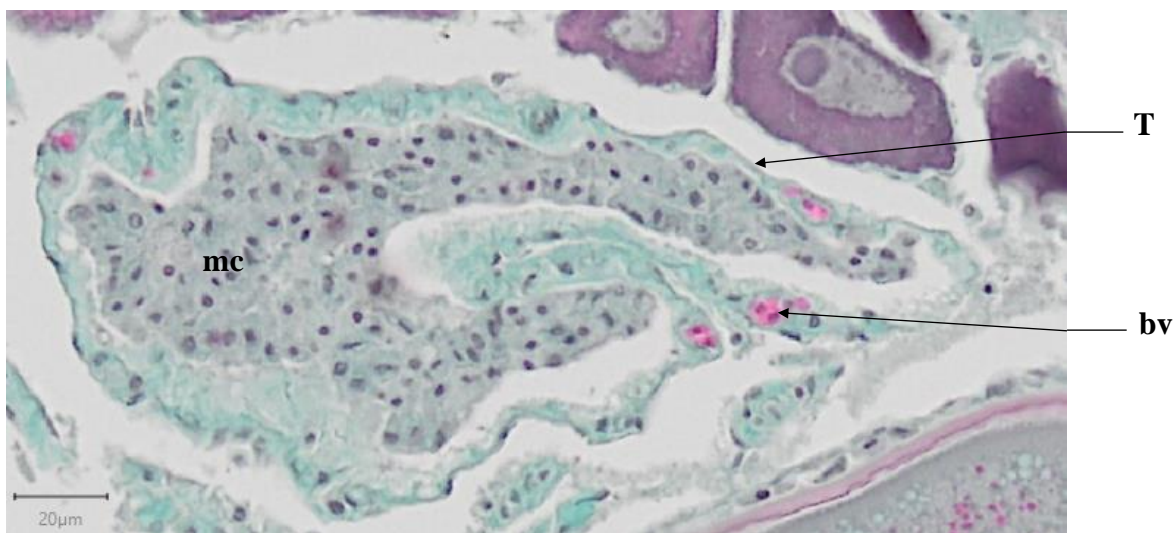


Figure 23 : Post-Ovulatory Follicle (**POF**), with the theca (**T**) left behind, with blood vessels (**bv**). Macrophage cells (**mc**) are present in the **POF**'s cavity

Atresia (aoA & aoB) and Lysis (L)

Torres-Martínez *et al.* (2017) defined atresia as the degeneration, reabsorption, or even ablation, of ovarian follicles. In general, the first sign of atresia is the degeneration of the germinal vesicle of the oocyte, followed by the fragmentation of the zona pellucida (**zp**) that will take an irregular appearance. This will lead to an hypertrophy of the follicular cells. There can be cell differentiations of the follicular cells (**fc**) into phagocytes and/or macrophages (**mc**).

In this study, we will define two types of atresia. Oocytes in early atresia (**aoA**) and oocytes in late atresia (**aoB**). **aoA** are all germinal cells in lysis, from the oogonium (**og**) stage until the **undischarged** hydrated oocyte (**oh**) stage. They will always be encased in somatic cells (follicular cells (**fc**) and/or theca (**T**)). **aoB** are all hydrated oocytes in lysis that have been **discharged**, and are thus not encased in somatic cells anymore. Since an **aoB** is a cellular structure in lysis in the middle of the **lumen**, their shapes will often be warped, scattered and surrounded by lysis (**L**).

Identification : An **aoA** is a **follicle in lysis**. This means that the **oocyte is still encased inside a theca, within the ovarian lamella**, but is undergoing lysis : degeneration of the germinal vesicle of the oocyte, fragmentation of the zona pellucida (**zp**) with an irregular appearance, hypertrophy of follicular cells. Phagocytes and/or macrophages (**mc**) may be present between the Theca (**T**) and the **zp**.

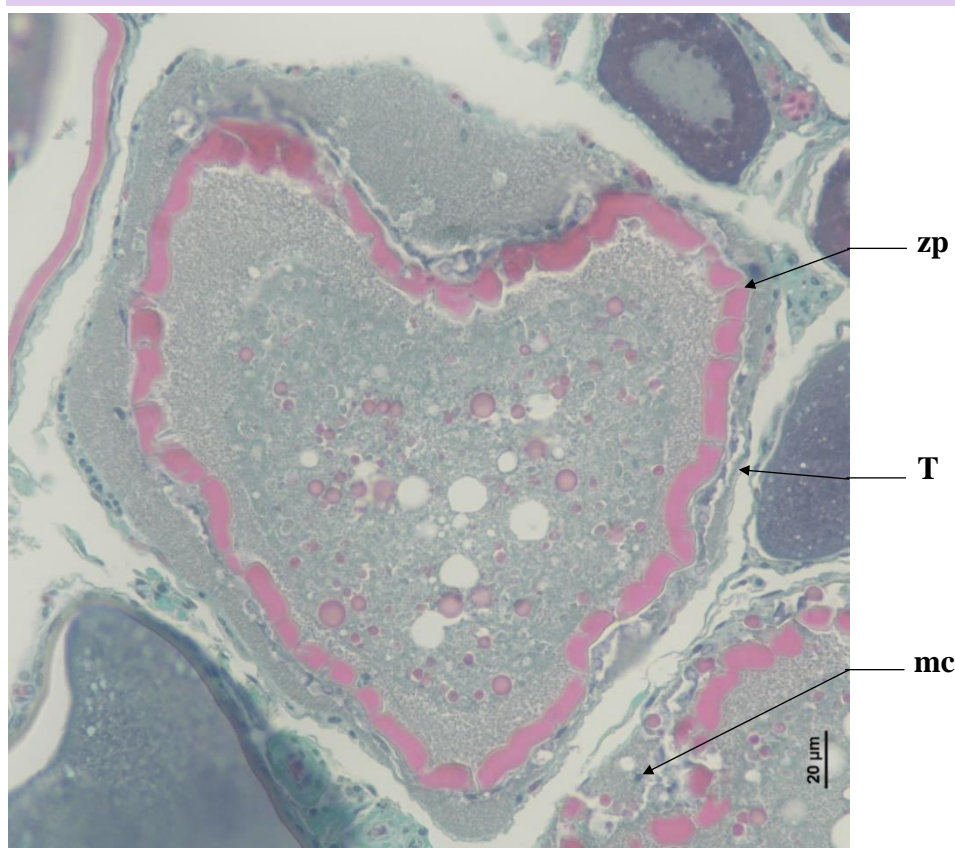
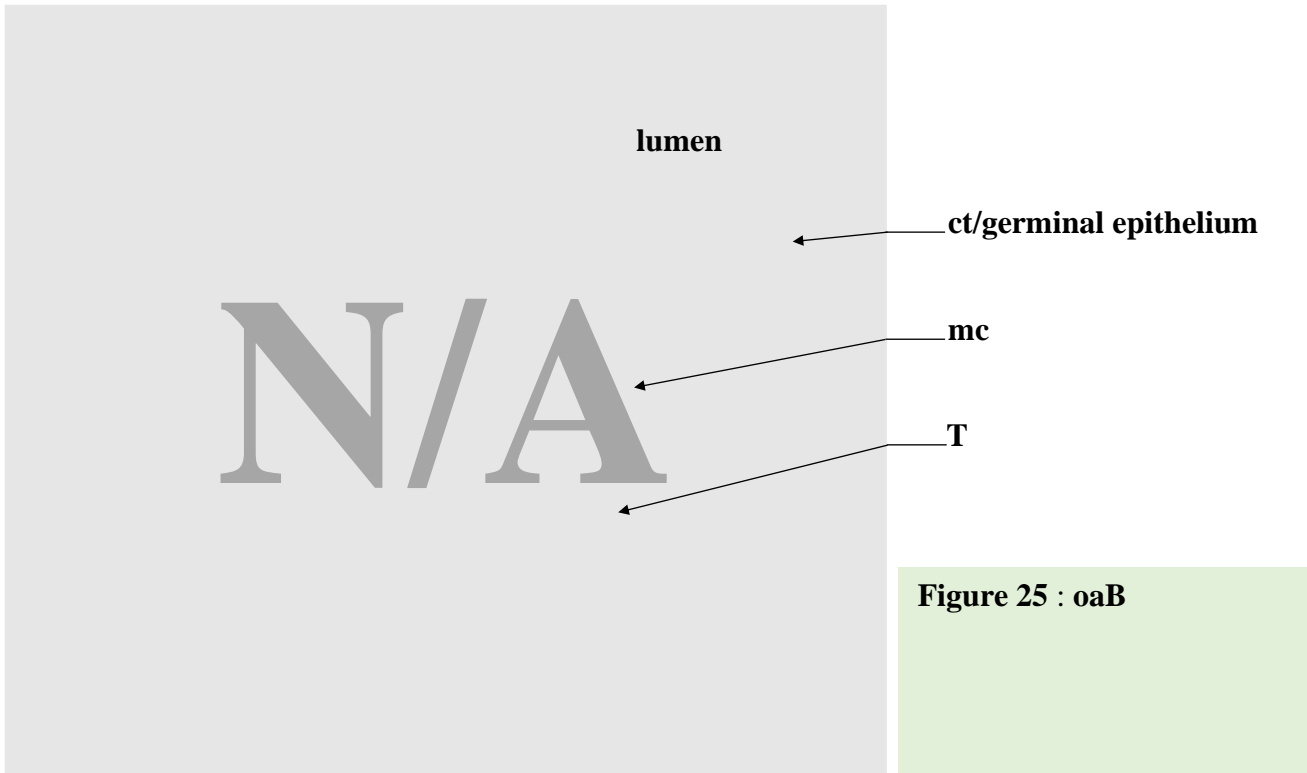


Figure 24 : Oocyte in early atresia (**aoA**). The oocyte has not been discharged into the **lumen**, and the follicle is still encased by its theca (**T**). the zona pellucida (**zp**) is distorted and macrophage cells (**mc**) can be seen between the **zp** and **T**

Identification : An **oaB** is a **discharged follicle in lysis**. This means that the **oocyte is in the lumen without a theca** and is undergoing lysis. The mature follicle may show fragmentation of its zona pellucida (**zp**) that will take an irregular appearance. Possible presence of macrophage cells lysis.



Identification : Lysis can be difficult to identify, especially with the presence of atresia. They can be found **anywhere inside the gonad, at any maturity phase**. This **cluster of cells in lysis** can contain macrophages, are of **different shapes and sizes**, and do **not possess a theca and/or zona pellucida**

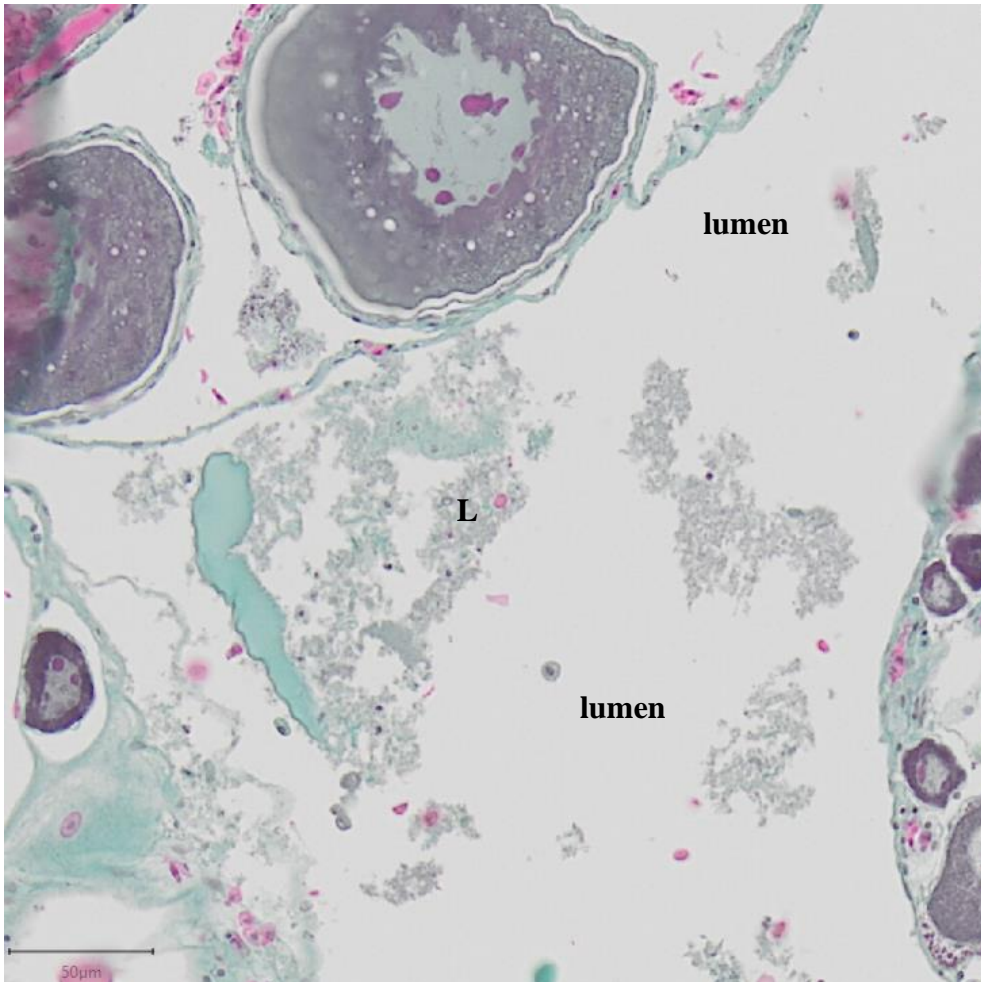


Figure 26 : Lysis (L) in the lumen

Connective tissue (ct) & Gonadal wall (gw)

The connective tissue (**ct**) links all ovarian structures together to form the ovarian lamellas. Follicles can be found inside the ovarian lamellas, encased in **ct**.

With the trichrome stain, connective tissue (**ct**) is made of green-colored cells, just like the cells that make up the gonad wall (**gw**). Gonad wall cells are muscular tissue while **ct** is not.

The gonad wall (**gw**) will have the same green tint as the **ct**. Muscle bundles and blood vessels (**bv**) can be found in the **gw**.

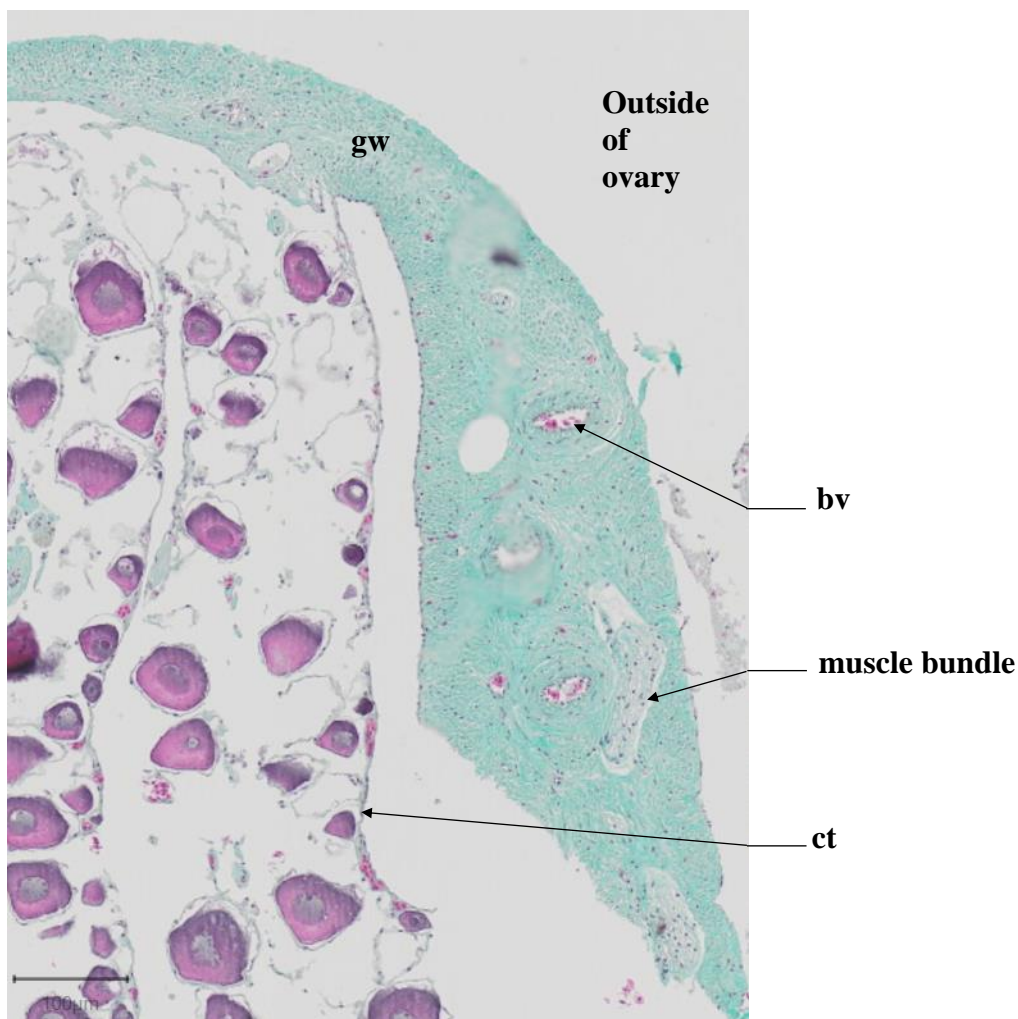


Figure 27 : Cross section of a red striped mullet ovary with its gonad wall (**gw**). The ovarian lamellas are held together by connective tissue (**ct**), delimiting the **lumen** and the outside of the ovary. Blood vessels (**bv**) and **muscle bundles** can be seen

Blood vessel (bv)

Blood vessels (**bv**) are numerous and of variable diameter, with a size that can vary from that of a single cell to over 100 μ m.

Found within a follicle's theca (**T**) or the gonad wall (**gw**), blood vessels (**bv**) are identifiable by the presence of blood cells (small red cells with a darker nucleus).

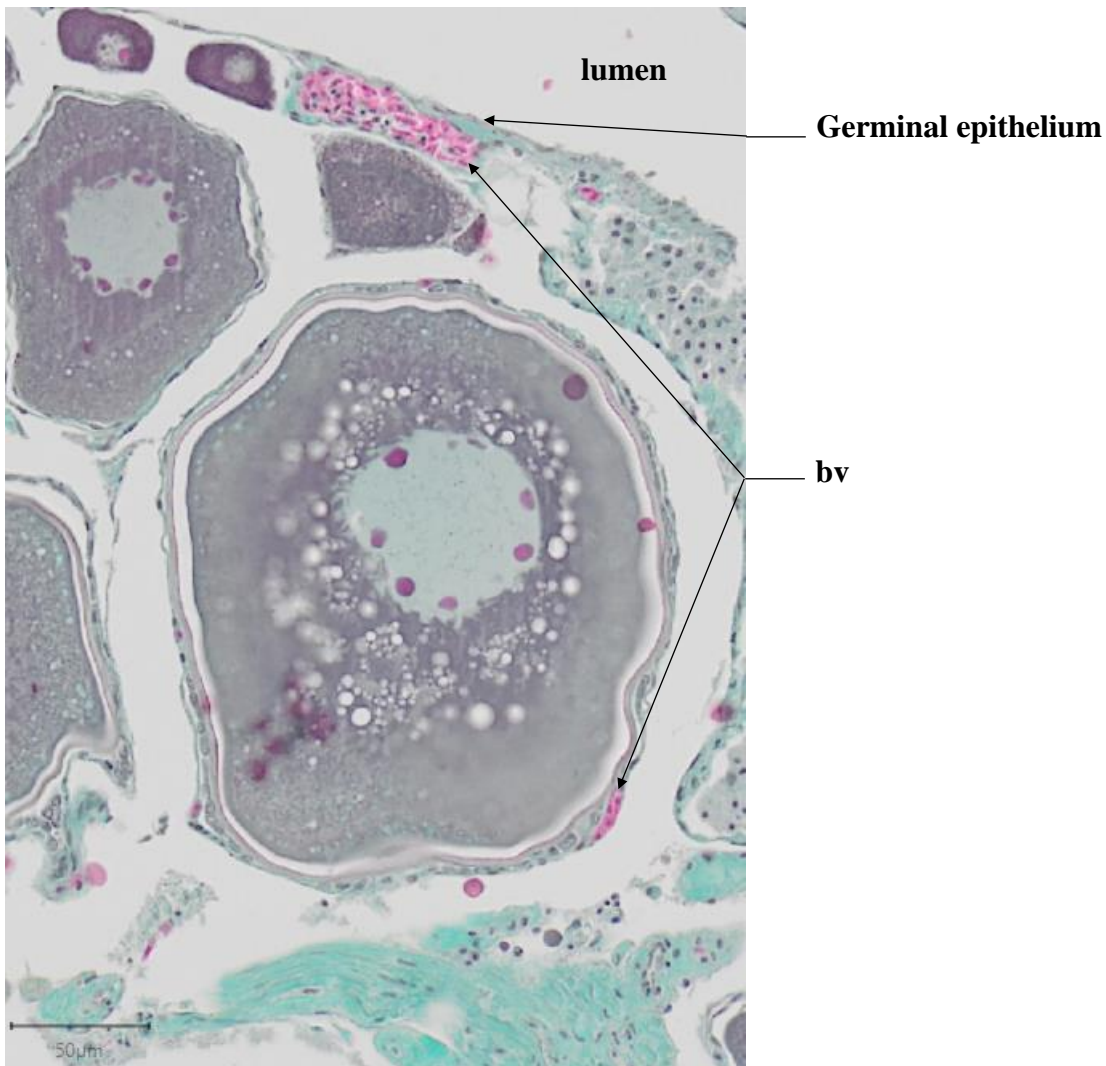


Figure 28 : Presence of blood vessels (**bv**) in the theca (**T**) of a cao, as well as in the **germinal epithelium** of the lamella

Bibliography

Anderson, E., 1969. Oocyte-follicle Cell Differentiation in Two Species of Amphineurans (Mollusca), *Mopalia mucosa* and *Chaetopleura apiculata*. J. Morphol. 129, 89-126.

Anderson, E., 1968. Cortical alveoli formation and vitellogenesis during oocyte differentiation in the Pipefish, *Syngnathus fuscus*, and the Killifish, *Fundulus heteroclitus*. J. Morphol. 125, 23-60.

Aragón, L., Aranda, G., Santos, A., Medina, A., 2010. Quantification of ovarian follicles in bluefin tuna *Thunnus thynnus* by two stereological methods. J. Fish Biol. 77, 719-730.

Brown-Peterson, N.J., Wyanski, D.M., Saborido-Rey, F., Macewicz, B.J., Lowerre-Barbieri, S.K., 2011. A Standardized Terminology for Describing Reproductive Development in Fishes. Mar. Coast. Fish. 3, 52-70.

Domínguez-Castanedo, O., Uribe, M.C., Rosales-Torres, A.M., 2016. Morphological development of the structures related to annualism in the ovarian follicle of the killifish *Millerichthys robustus* (Costa,1995) (Teleostei: Cyprinodontiformes). J. Morphol. 277, 1219-1230.

Gabe, M., 1968. Techniques Histologiques, 2ème ed. Masson et C., Paris.

ICES, 2008. Report of the Workshop on Maturity Ogive Estimation for Stock Assessment (WKMOG), 3-6 June 2008, Lisbon, Portugal. ICES CM2008/ACOM:33. 72 pp.

ICES, 2010. Report of the ICES/HELCOM Workshop on Flatfish in the Baltic Sea (WKFLABA), 8-11 November 2010, Öregrund, Sweden. ICES CM 2010/ACOM:68. 85pp.

ICES, 2012 Report of the Workshop for maturity staging chairs (WKMATCH), 11-15 June 2012, Split, Croatia. ICES CM 2012/ACOM:58. 57 pp.

ICES, 2018. Report of the Workshop for Advancing Sexual Maturity Staging in Fish (WKASMSF), 30 April - 4 May 2018, ICES Headquarters, Copenhagen, Denmark. ICES CM/EOSG: 38. 75 pp.

ICES, 2019. Working Group on Biological Parameters (WGBIOP), 7-10 October 2019, Lisbon, Portugal. ICES Scientific Reports. 1:85. 93 pp.

Lowerre-Barbieri, S.K., Brown-Peterson, N.J., Murua, H., Tomkiewicz, J., Wyanski, D.M., Saborido-Rey, F., 2011. Emerging Issues and Methodological Advances in Fisheries Reproductive Biology. Mar. Coast. Fish. 3, 32-51

Robson, S.M., 2004. Age, growth, reproductive biology and population dynamics of the common megrim *Lepidorhombus whiffiagonis* (Walbaum, 1792) from off the west coast of Ireland. Unpublished thesis (Doctor of Philosophy in Fisheries Biology), Galway-Mayo Institute of Technology.

Sauger, C., Quinquis, J., Dubroca, L., Parrad, S., Kellner, K., Heude-Berthelin, C., 2019. Sample collection protocol for the extraction of female gonads in the megrim (*Lepidorhombus spp.*) for maturity staging through histology. IFREMER, <https://doi.org/10.13155/70724>

Sauger, C., Dubroca, L., Villain-Naud, N., Kellner, K., Heude-Berthelin, C., Elie, N., 2020. Protocol for the determination of histological structures found in the ovaries and during the oogenesis of the megrim, *Lepidorhombus whiffiagonis* (Walbaum, 1792). IFREMER

Torres-Martínez, A., Hernández-Franyutti, A., Uribe, M.C., Contreras-Sánchez, W.M., 2017. Ovarian structure and oogenesis of the extremophile viviparous teleost *Poecilia mexicana* (Poeciliidae) from an active sulfur spring cave in Southern Mexico. *J. Morphol.*, Wiley Periodicals 278, 1667-1681.

Tyler, C.R., Sumpter, J.P., 1996. Oocyte growth and development in teleosts. *Rev. Fish Biol. Fish.*, Chapman & Hall 6, 287-318.

